

Children's Mercy Kansas City

SHARE @ Children's Mercy

Presentations

7-1-2020

Congenital Abnormalities of the Lower Airways and Lungs

Christopher M. Oermann
Children's Mercy Hospital

Let us know how access to this publication benefits you

Follow this and additional works at: <https://scholarlyexchange.childrensmercy.org/presentations>



Part of the [Pediatrics Commons](#), and the [Pulmonology Commons](#)

Recommended Citation

Oermann, Christopher M., "Congenital Abnormalities of the Lower Airways and Lungs" (2020).
Presentations. 53.
<https://scholarlyexchange.childrensmercy.org/presentations/53>

This Presentation is brought to you for free and open access by SHARE @ Children's Mercy. It has been accepted for inclusion in Presentations by an authorized administrator of SHARE @ Children's Mercy. For more information, please contact hlsteel@cmh.edu.

Congenital Abnormalities of the Lower Airways and Lungs

Christopher M Oermann, MD

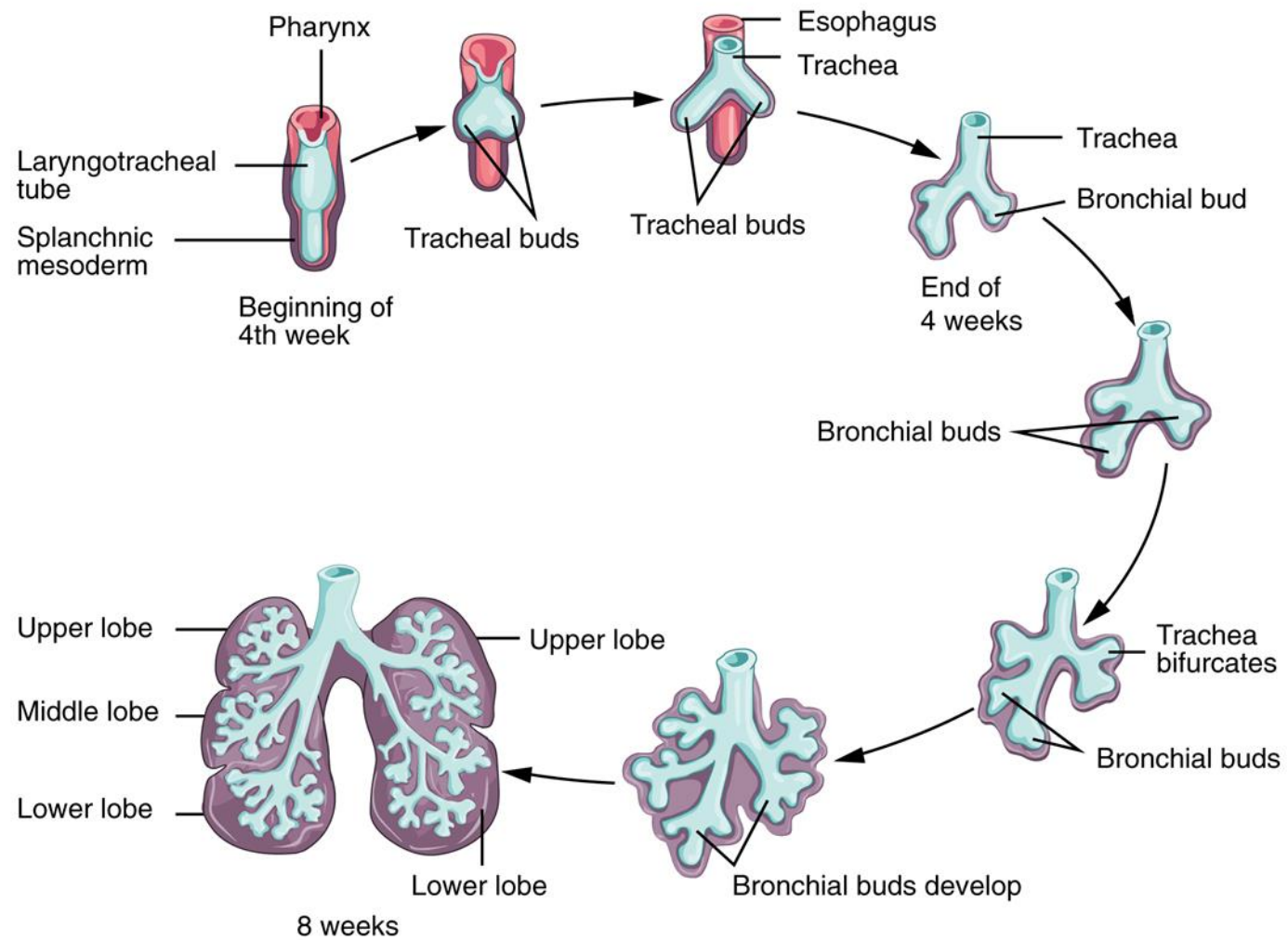
Division Director, Allergy, Immunology, Pulmonary and Sleep
Medicine, Children's Mercy Kansas City

Professor of Pediatrics, UMKC

Professor of Clinical Pediatrics, KUMC

Goals and Objectives

- Participants will be able to:
 - Describe the 5 stages of fetal lung development
 - Summarize the prenatal identification and management of congenital abnormalities of the lower airways and lung (CALAL)
 - Explain the classification of CALAL
 - Compare the clinical characteristics, pathology, and management of common CALAL
 - Discuss the long term prognosis of CALAL



EMBRYOLOGY

Embryology

- Embryogenesis controlled by “master control genes” coding for a variety of transcription, growth, cell adhesion, and other factors
- Lungs develop from outpouching of laryngotracheal sulcus at caudal end of medial pharyngeal groove on ventral surface of foregut by week 4 of gestation
- Respiratory epithelium develops from endoderm
- Pleura, vascular structures, and airway support develop from mesoderm

Stages of Development*

- **Embryonic Period**

- Weeks 4-6
- Foregut endoderm forms tubules which invade splanchnic mesoderm
 - Formation of mainstem, lobar, and segmental bronchi
- Columnar epithelium
- Rudimentary vessels with no cartilage, smooth muscle, or nerves

*Whitsett & Wert. Kendig's
Disorders of the Respiratory
Tract in Children. Chp 1 pp 1-16.
Saunders Philadelphia, PA 2006.

- **Pseudoglandular Period**

- Weeks 7-16
- Continued tubular development of terminal bronchioles and primitive acini
- Epithelial differentiation with multiple cell types
 - Cells producing surfactant proteins A, B, C
 - Neuroepithelial cells
- Vascular structures parallel airways where cartilage and smooth muscle develop

- **Canalicular Period**

- Weeks 16-26
- Development of respiratory bronchioles, acini, and primitive alveoli
- Ongoing epithelial differentiation with transition to metabolically active cuboidal cells in distal airways and acini
- Ongoing vascularization and early capillarization

- **Saccular Period**

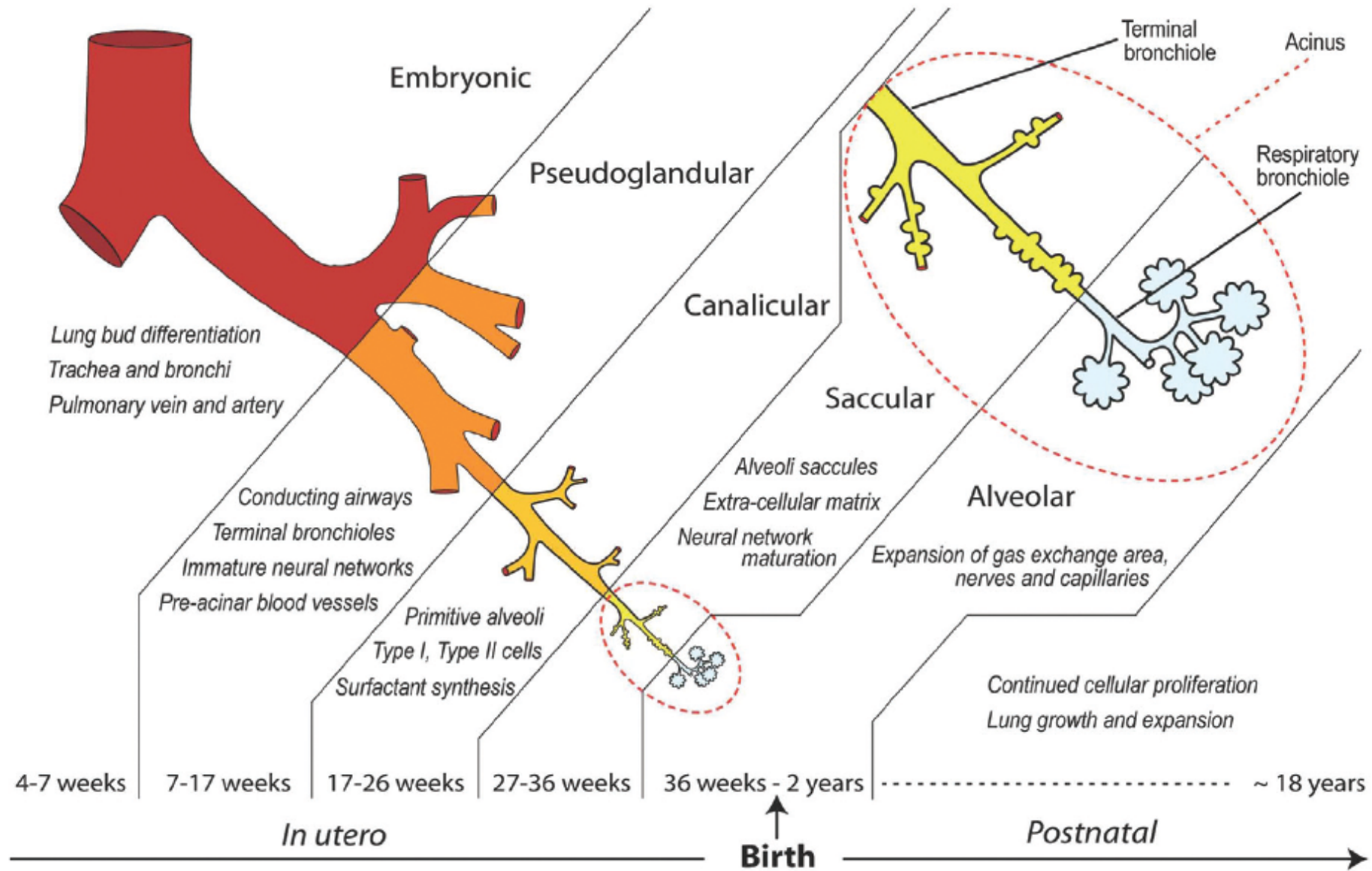
- Weeks 26-36
- Maturation of acini and primitive alveoli (squamous Type I pneumocytes), surrounding capillary network, and support structures

- **Alveolar Period**

- Weeks 36 – birth
- Increasing size and number of alveoli
- Complete maturation of all lung tissue

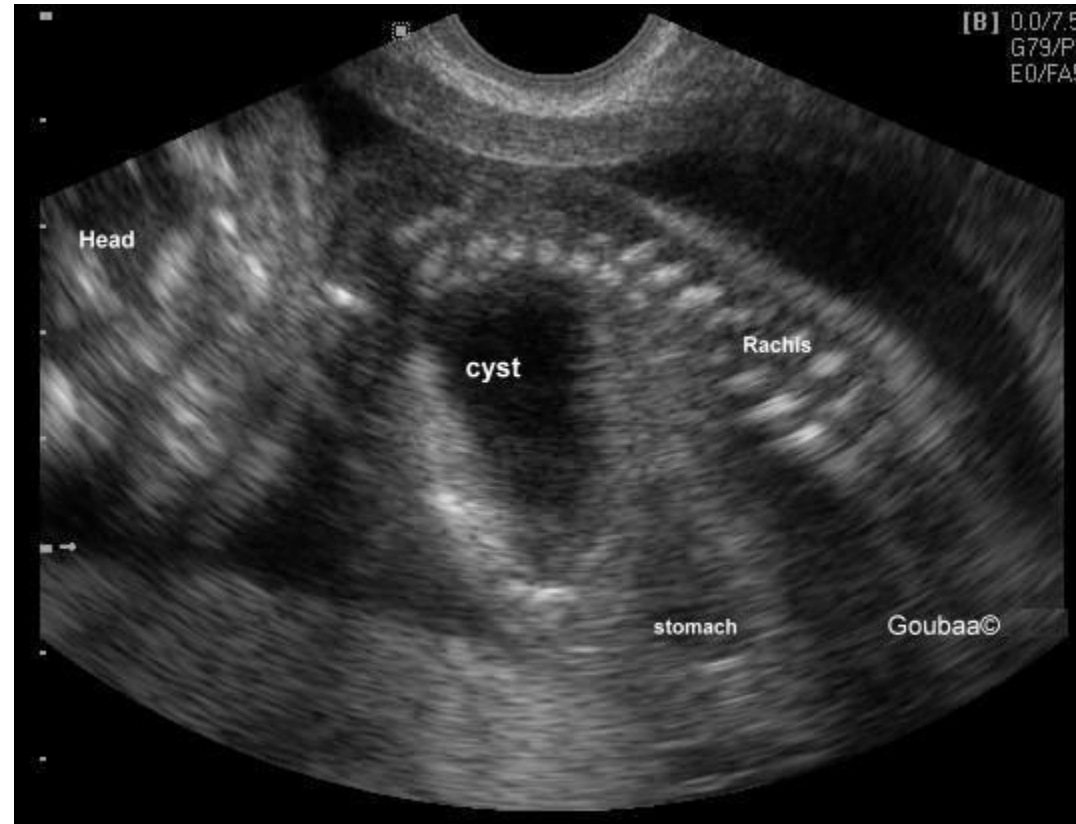
- **Postnatal**

- Ongoing alveolar development
 - ↑ number of alveoli until age 5 (or older)
 - ↑ size of alveoli until adulthood



Kajekar R. 2007.
 Environmental factors
 and developmental
 outcomes in the lung.
 Pharmacol Therap
 114:129-145

Stage	Gestational Age	Major Events	CALAL
Embryonic	4-6	Lung bud differentiation Mainstem & segmental bronchi (Gen 1-4 airways)	Stocker 0 CPAM BGC ELS TEF
Pseudoglandular	6-16	Subsegmental bronchi Terminal bronchioles (Gen 5-20 airways) Cartilage Glands Smooth muscle	Stocker I CPAM ILS CDH impacts branching
Canalicular	16-26	Respiratory bronchioles (Gen 20+ airways) Primitive alveoli Vascularization Type I and Type II pneumocytes	Stocker II, III CPAM Alveolar Capillary Dysplasia
Saccular	26-36	Functional alveoli	Stocker III CPAM
Alveolar	36 - birth	↑ Size and number of alveoli Capillarization	Stocker IV CPAM CLE Alveolar simplification
Postnatal	Birth - ? years	Ongoing alveolar development ↑ Number; birth – 5 years ↑ Size > 5 years	



<http://www.medicalechography.com/IMAGES/312thymic.htm>

PRENATAL IDENTIFICATION AND MANAGEMENT

Question 1

As a consultant in the Fetal Health Center at your hospital, you have been asked to counsel the parents of an 18-week EGA fetus in whom a right lower lobe single-cyst lung abnormality has been identified.

In responding to the parents questions about prognosis, the most accurate statement is:

- A. Associated abnormalities are common
- B. Complete resolution of congenital lung abnormalities is probable
- C. Continued growth of congenital lung abnormalities is probable
- D. Growth of congenital lung lesions is varied and unpredictable

Question 1

As a consultant in the Fetal Health Center at your hospital, you have been asked to counsel the parents of an 18-week EGA fetus in whom a right lower lobe single-cyst lung abnormality has been identified.

In responding to the parents questions about prognosis, the most accurate statement is:

- A. Associated abnormalities are common
- B. Complete resolution of congenital lung abnormalities is probable
- C. Continued growth of congenital lung abnormalities is probable
- D. **Growth of congenital lung lesions is varied and unpredictable**

Prenatal Diagnosis and Management

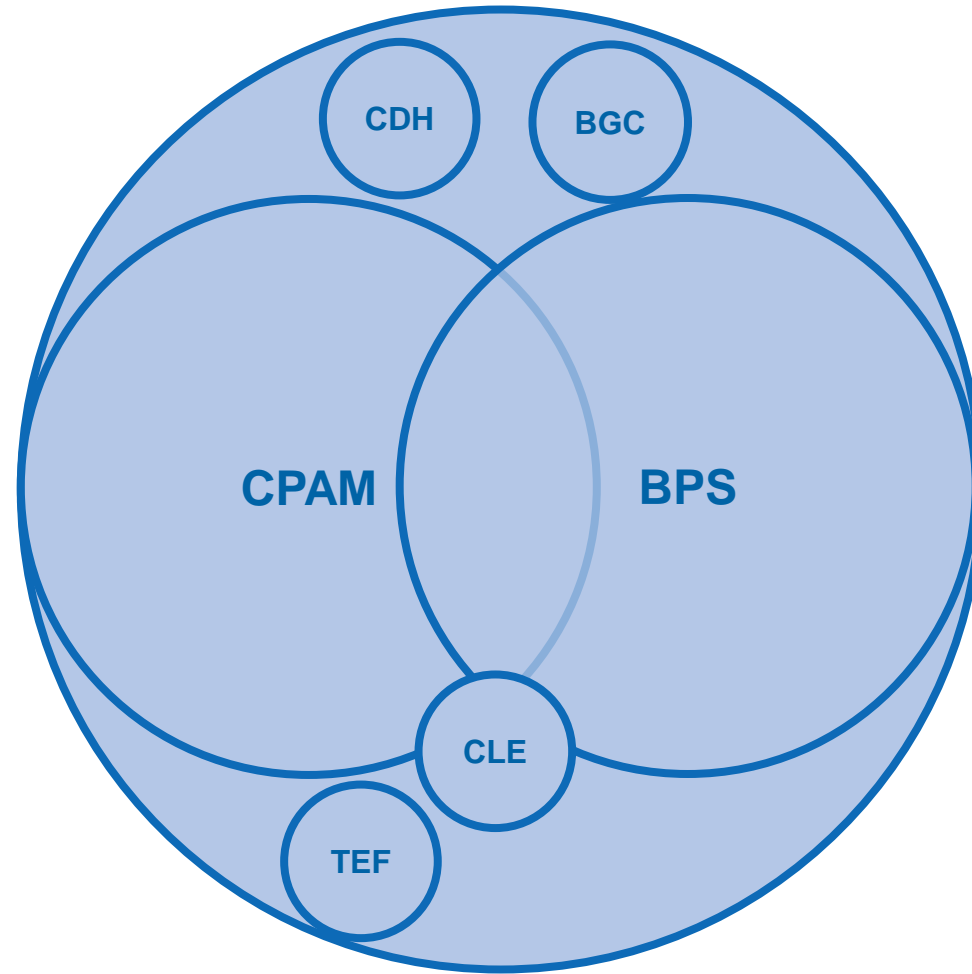
- Diagnosis
 - Prenatal ultrasound
 - Can identify both cystic and solid lesions
 - Associated congenital anomalies and complications can be seen
 - CLE not easily diagnosed
 - MRI may be helpful in differentiating some lesions types of lesions
 - Definitive prenatal diagnosis often not possible
 - Don't speculate
 - Prepare for worst case scenario at delivery

- Natural History
 - Unpredictable changes in size and character through gestation
 - Mass effect can lead to lung hypoplasia, esophageal obstruction with polyhydramnios, and hydrops (ascites, pleural and pericardial effusions, and edema)
 - Hydrops associated with poor outcome without intervention
 - Although regression common, complete resolution is vanishingly rare
 - All CALAL identified by prenatal ultrasound require advanced postnatal imaging

- Management

- Comprehensive evaluation including ultrasound, echocardiogram, MRI, and karyotype is needed prior to intervention
 - Intervention only appropriate if above suggest good long term outcome
- Fewer than 10% of prenatally identified lesions require fetal intervention
 - Infants without hydrops should undergo spontaneous delivery
 - Infants > 32 weeks with hydrops should undergo elective delivery
 - Infants < 32 weeks with hydrops should undergo fetal intervention

- Fetal interventions include
 - Thoracentesis
 - Most useful for lesions with a single large cyst
 - Repeat procedure may be necessary
 - Thoracoamniotic shunt (single cyst)
 - Fetal Surgery (multi-cystic)
 - Ex-utero Intrapartum Therapy (EXIT) procedure
 - Infant delivered via C-section
 - Procedure carried out with placenta intact maintaining fetal circulation

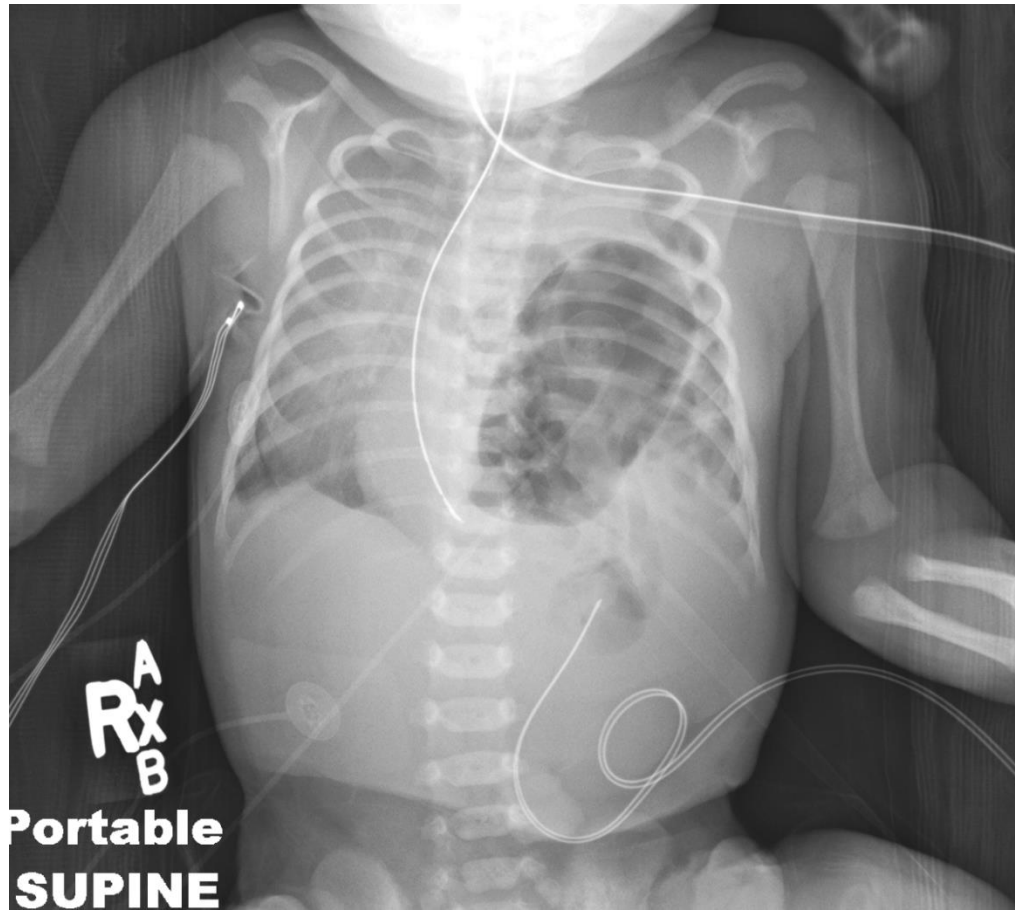

CLASSIFICATION

Classification

- Current convention recognizes four cystic abnormalities
 - Congenital Pulmonary Airway Malformation (CPAM formerly CCAM)
 - Congenital Lobar Emphysema (Over-inflation)
 - Pulmonary Sequestration
 - Intralobar
 - Extralobar
 - Bronchogenic Cyst

- Recent publications suggest that:
 - Overlap exists between a number of lesions
 - Many lesions don't fit into historic classifications
 - Bronchial atresia/stenosis/obstruction
 - Common finding
 - Possible unifying etiologic pathology
- Not technically congenital lung malformations but.....
 - Congenital Diaphragmatic Hernia (CDH)
 - Esophageal Atresia with Tracheo-Esophageal Fistula (TEF)



CLINICAL CHARACTERISTICS, PATHOLOGY, AND MANAGEMENT

Question 2

You have been asked to consult on a term infant whose chest radiograph demonstrates a cystic abnormality in the right upper lobe. The lesion appears to be comprised of multiple cysts up to 2 cm in diameter (Stocker Type II).

Which of the following statements regarding this lesion is true:

- A. Associated anomalies rarely accompany this type of lesion
- B. Males and females are equally affected
- C. Most CPAM are of this type
- D. Pleuropulmonary blastoma is frequently associated with this lesion

Question 2

You have been asked to consult on a term infant whose chest radiograph demonstrates a cystic abnormality in the right upper lobe. The lesion appears to be comprised of multiple cysts up to 2 cm in diameter (Stocker Type II).

Which of the following statements regarding this lesion is true:

- A. Associated anomalies rarely accompany this type of lesion
- B. Males and females are equally affected**
- C. Most CPAM are of this type
- D. Pleuropulmonary blastoma is frequently associated with this lesion

CPAM

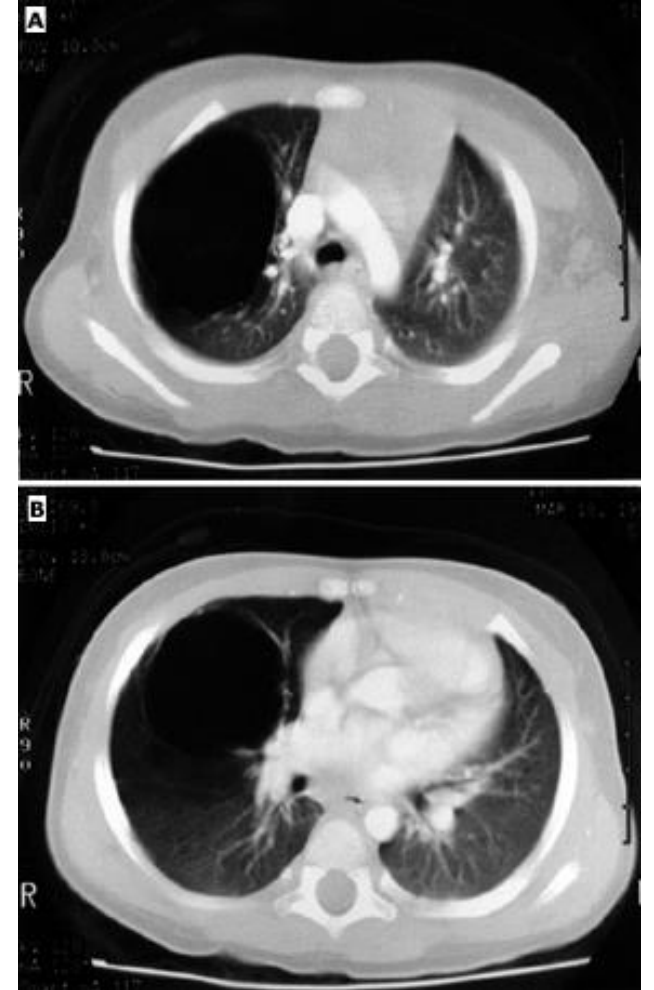
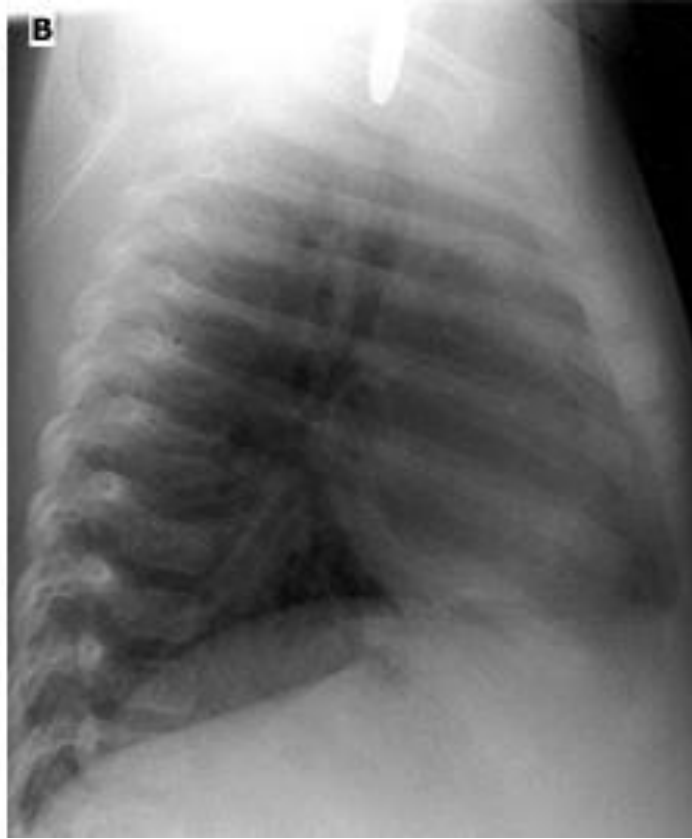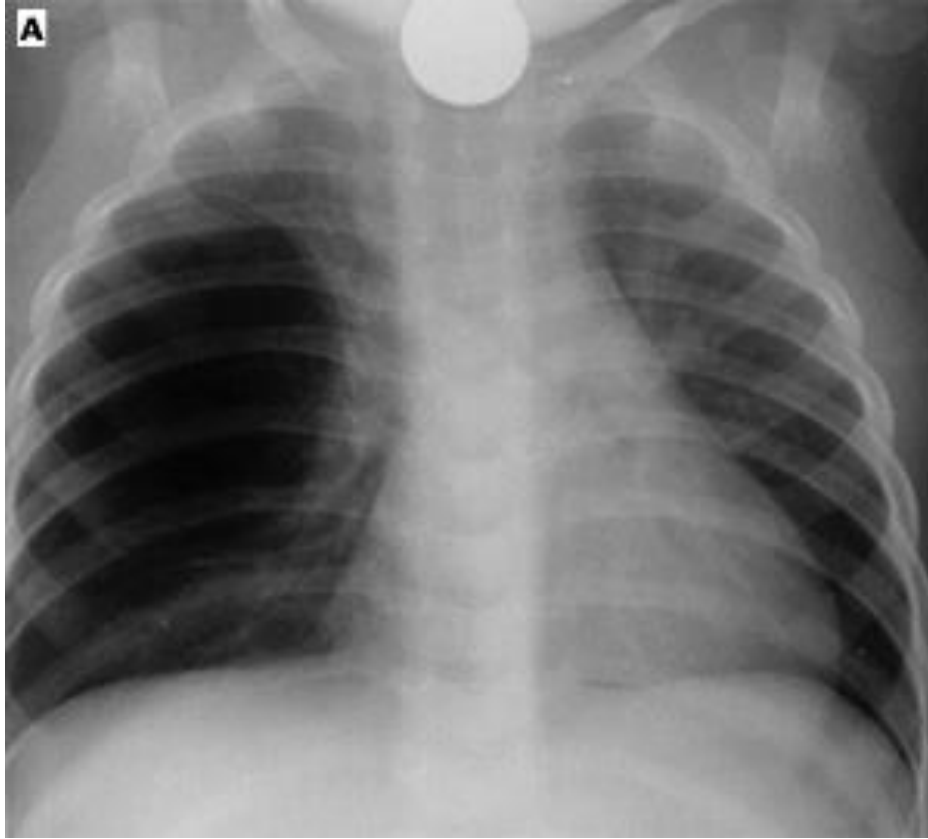- Epidemiology
 - Incidence of 1 in 10,000
 - M:F = 1:1
 - Majority identified on prenatal ultrasound
- Pathophysiology
 - Stocker classification
 - Stocker 0 – 1-3% of cases, early gestation, small cysts comprised of tracheal/bronchial tissue, incompatible with life
 - Stocker I – 60-70% of cases, later gestation, large single cyst, bronchiolar tissue

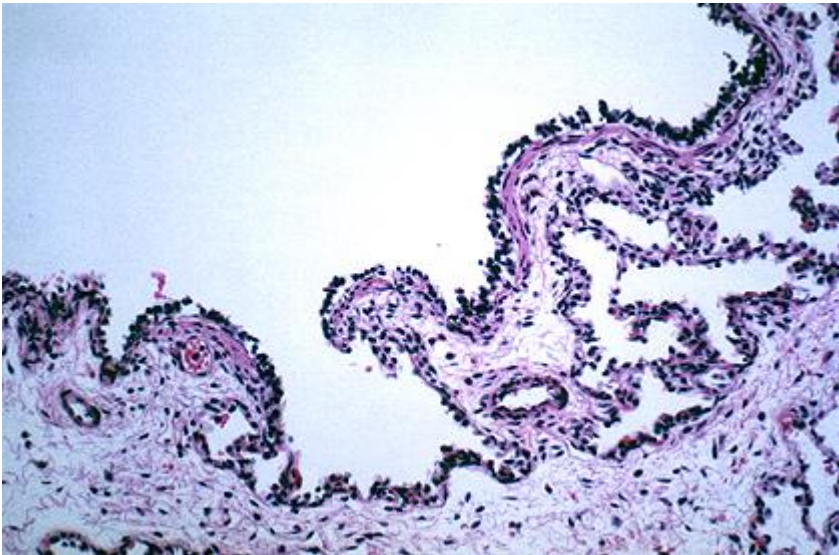
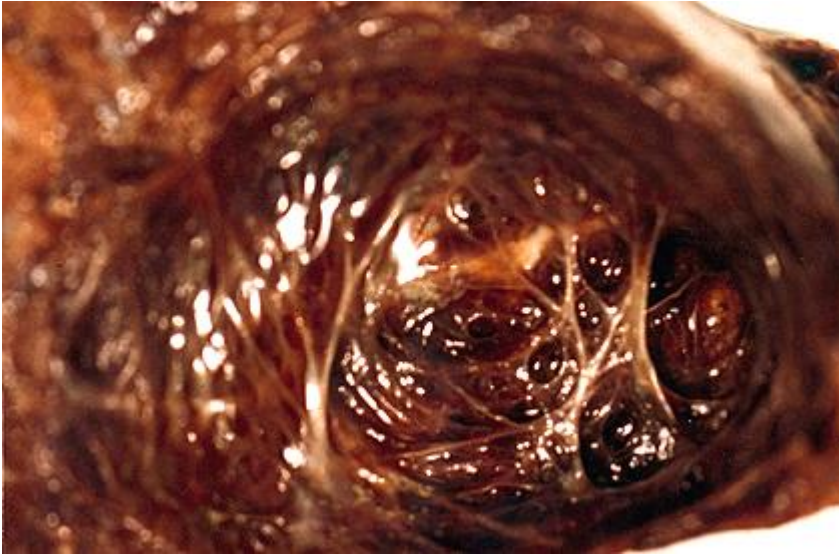
- Stocker II – 15-20% of cases, mid-gestation, 60% associated with other anomalies, multiple small cysts of variable size, bronchiolar tissue
- Stocker III – 5-10% of cases, early gestation, massive solid lesions with poor prognosis, acinar tissue
- Stocker IV – 10-15% of cases, later gestation, single large cyst, alveolar tissue, strong association with PPB
- Connected to airways
- Equal distribution in all lobes

- Clinical Characteristics
 - ¼ of patients symptomatic in neonatal period; tachypnea, respiratory distress, cyanosis
 - ¾ of patients symptomatic later in life; recurrent infection, pneumothorax, hemorrhage, malignancy
- Management and Prognosis
 - All CPAM require resection*
 - Long term outcomes generally good for Stocker Type I and variable for other types

* Significant debate regarding management of asymptomatic patients

Type I CPAM

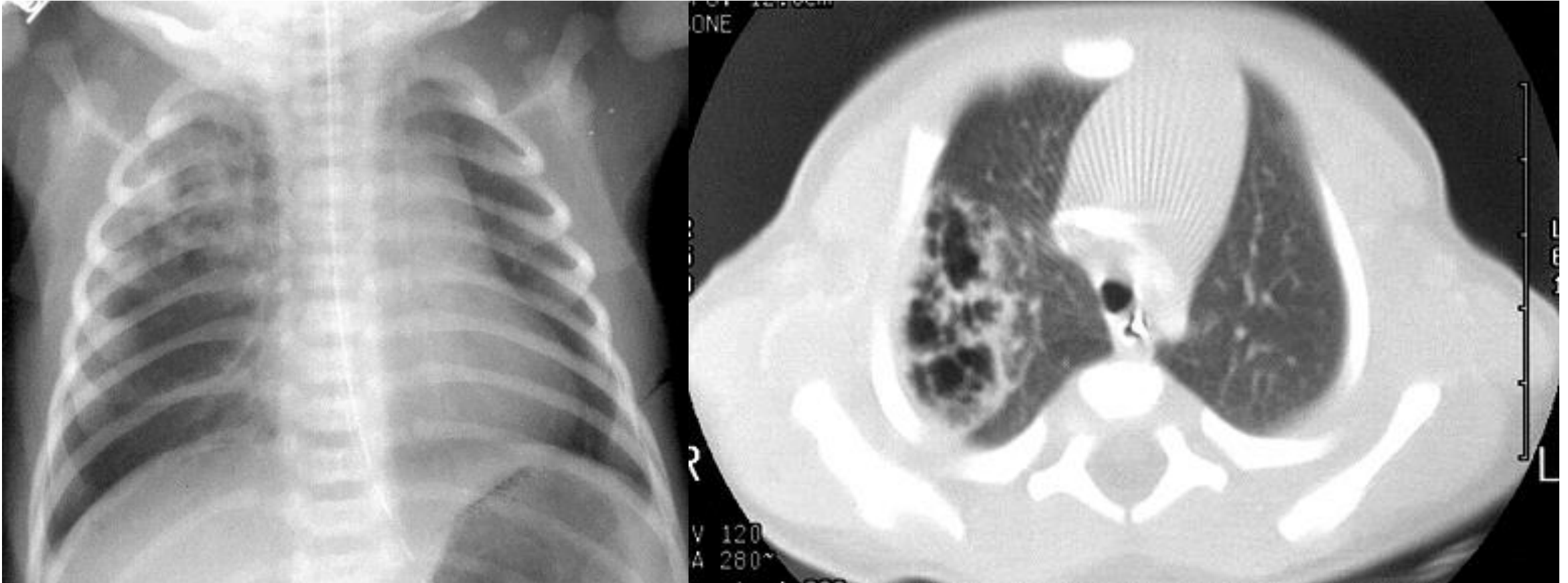


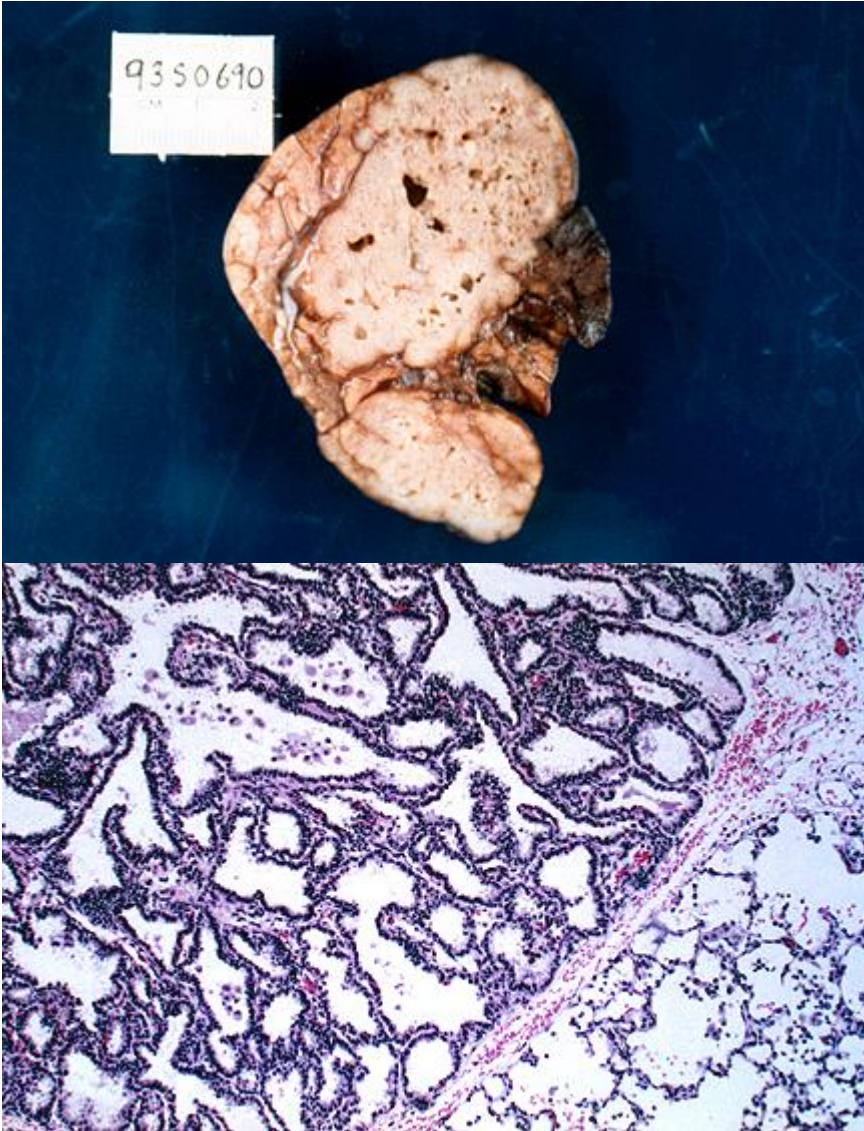


Histology specimen from a Stocker Type I CPAM showing the large cystic component lined by columnar, ciliated epithelium. The wall of the cyst resembles pre-acinar airways. Frequent openings in the cyst wall extend into the adjacent acinar structures. The wall contains smooth muscle but not cartilage.

Courtesy Claire Langston
Previously published in
UpToDate

Type II CPAM





Histology specimen from a Stocker Type II CPAM showing structures resembling terminal bronchioles which are lined by low columnar to cuboidal epithelium separated by small amounts of connective tissue. Alveolar structures are not present in this specimen.

Courtesy Claire Langston
Previously published in
UpToDate

Pleuropulmonary Blastoma

- Most common lung malignancy in children
- Three pathologic stages
 - Type I – purely cystic
 - Type II – mixed cystic/solid
 - Type III – purely solid
- Associated with DICER1 mutations
- Difficult to differentiate Stocker Types I & IV CPAM and PPB
 - Family history, multifocal or bilateral cysts, postnatal diagnosis, and pneumothorax suggestive of PPB

Question 3

You are evaluating a two-year-old boy referred for recurrent lower respiratory tract infections. His chest radiograph demonstrates left upper lobe hyperinflation with mediastinal shift. Mother recalls that prenatal ultrasound was reported as normal. You suspect congenital lobar emphysema (CLE).

Which of the following characteristics makes this presentation **atypical**:

- A. Age at presentation
- B. Location of the lesion within the thorax
- C. Male sex
- D. Normal prenatal ultrasound

Question 3

You are evaluating a two-year-old boy referred for recurrent lower respiratory tract infections. His chest radiograph demonstrates left upper lobe hyperinflation with mediastinal shift. Mother recalls that prenatal ultrasound was reported as normal. You suspect congenital lobar emphysema (CLE).

Which of the following characteristics makes this presentation **atypical**:

- A. Age at presentation
- B. Location of the lesion within the thorax
- C. Male sex
- D. Normal prenatal ultrasound

Congenital Lobar Emphysema

- Epidemiology
 - Incidence of 1 in 20,000 to 1 in 30,000
 - M:F = 3:1
 - Majority identified postnatally (normal prenatal US)
 - Most are isolated abnormalities
- Pathophysiology
 - Histologically normal but enlarged airways and alveoli
 - Connected to airways (stenotic or obstructed)
 - Predominantly upper lobes

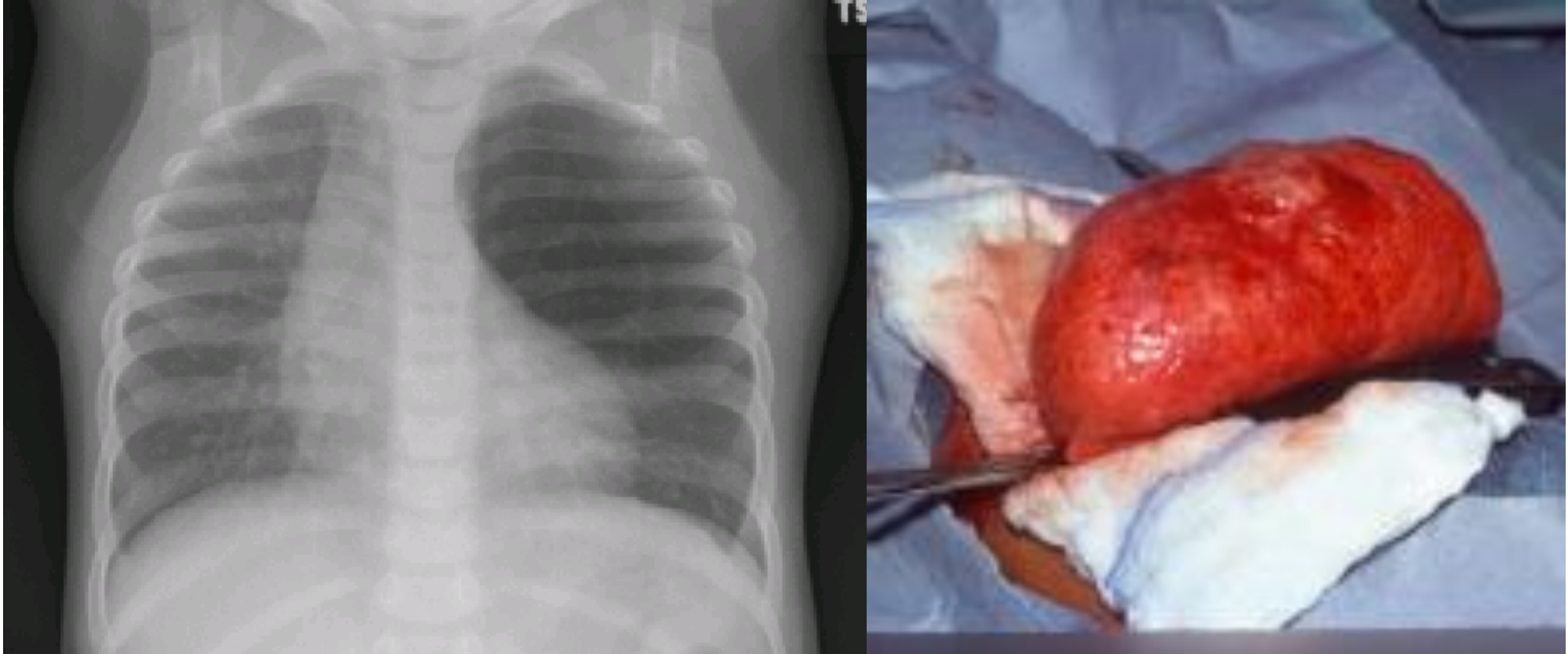
- Clinical Characteristics

- $\frac{1}{4}$ - $\frac{1}{3}$ symptomatic at birth; $\frac{1}{2}$ symptomatic by one month; nearly all symptomatic by 6 months
- Chest radiographs often normal at birth (or with opacification) but with progressive over-inflation
- Respiratory distress (tachypnea, increased work of breathing, +/- cyanosis), wheezing, decreased breath sounds, asymmetric chest

- Management and Prognosis

- Symptomatic CLEs should be resected
- Asymptomatic CLEs may be observed

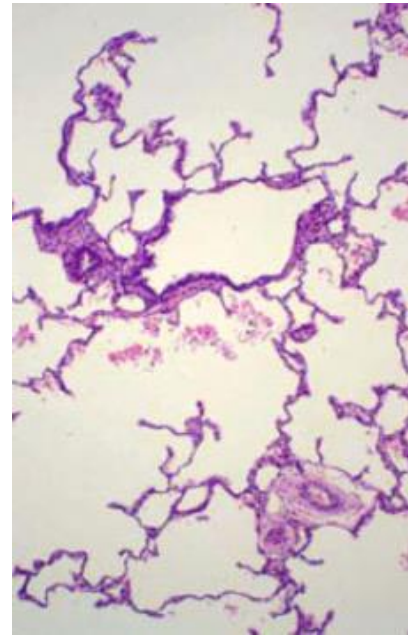
CLE



Courtesy Darryl Cass



Courtesy Claire Langston
Previously published in
UpToDate



Histology specimen from a CLE. The lobe remained fully inflated following resection. Histology demonstrates grossly dilated alveoli without true emphysematous changes.

Question 4

A 6-week old term male infant has been referred to your clinic for persistent tachypnea and increased work of breathing. His parents report that he has had several chest radiographs, all of which have been reported as normal. You order a chest CT which shows the presence of a pulmonary sequestration.

An extralobar pulmonary sequestration (ELS) is more likely than intralobar pulmonary sequestration (ILS) to be characterized by:

- A. Later diagnosis
- B. Male gender
- C. Pleural investiture within existing lobe
- D. Systemic arterial blood supply originating from the descending thoracic aorta

Question 4

A 6-week old term male infant has been referred to your clinic for persistent tachypnea and increased work of breathing. His parents report that he has had several chest radiographs, all of which have been reported as normal. You order a chest CT which shows the presence of a pulmonary sequestration.

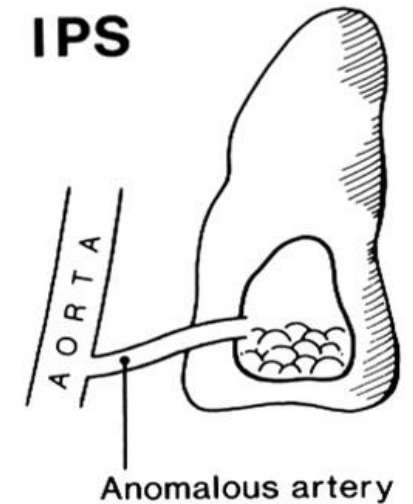
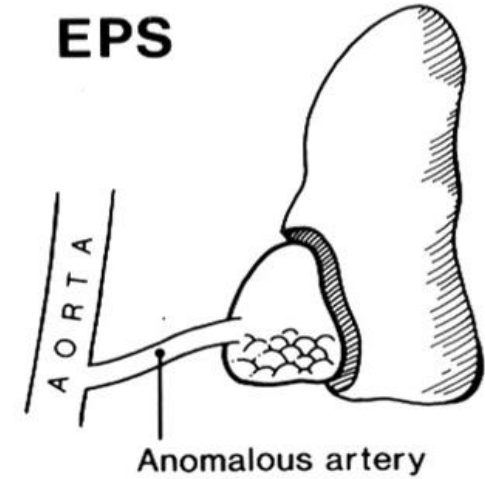
An extralobar pulmonary sequestration (ELS) is more likely than intralobar pulmonary sequestration (ILS) to be characterized by:

- A. Later diagnosis
- B. Male gender**
- C. Pleural investiture within existing lobe
- D. Systemic arterial blood supply originating from the descending thoracic aorta

Bronchopulmonary Sequestration

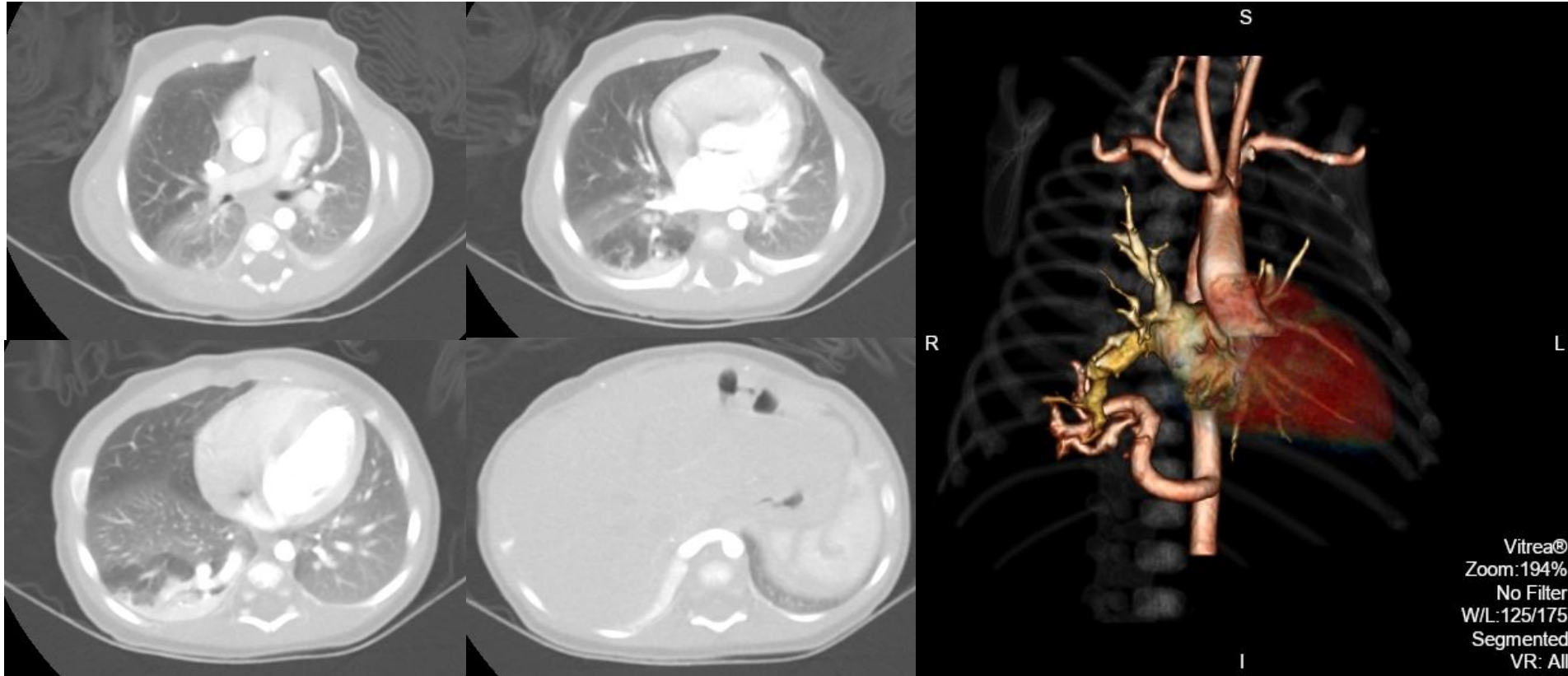
- Epidemiology
 - Incidence of 1 in 200,000 (ILS) to 800,000 (ELS)
 - M:F = 3:1 (ELS); 1:1 (ILS)
 - Diagnosis
 - ELS may be diagnosed on prenatal ultrasound
 - ILS diagnosed postnatally
- Pathophysiology
 - Abnormal microcystic lung tissue
 - No connection to airways
 - Systemic arterial connection

- No laterality; lower lobe predominance
- ELS with separate pleura; ILS contained within pleura of normal lung
- **Clinical Characteristics**
 - Symptoms develop from birth to adulthood
 - Respiratory distress seen in infants with ELS; recurrent pneumonia seen in older children and adults with ILS
 - Associated anomalies are present in 40% of ELS

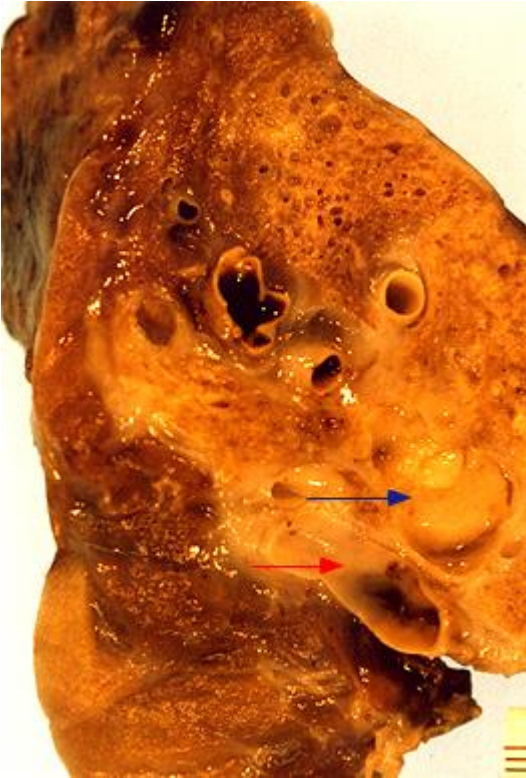


Samuel M, Burge DM. Thorax
1999;54:701-706.

- Prognosis and Management
 - Small, asymptomatic ELS may be observed
 - ILS generally require resection

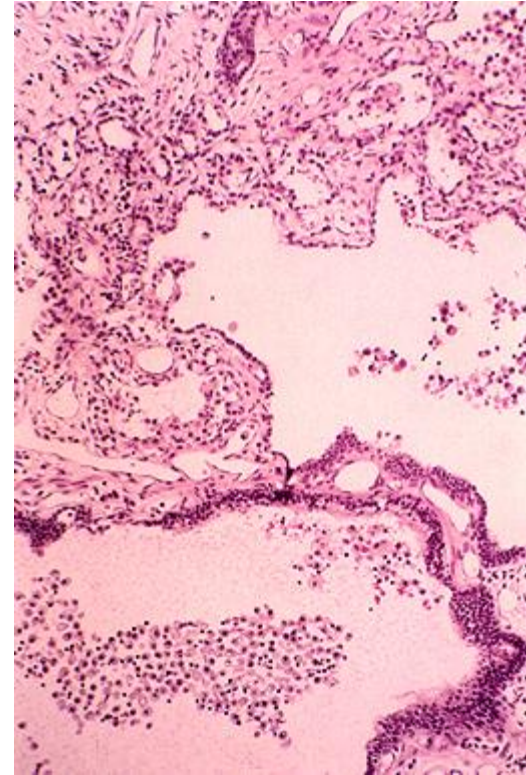


ILS



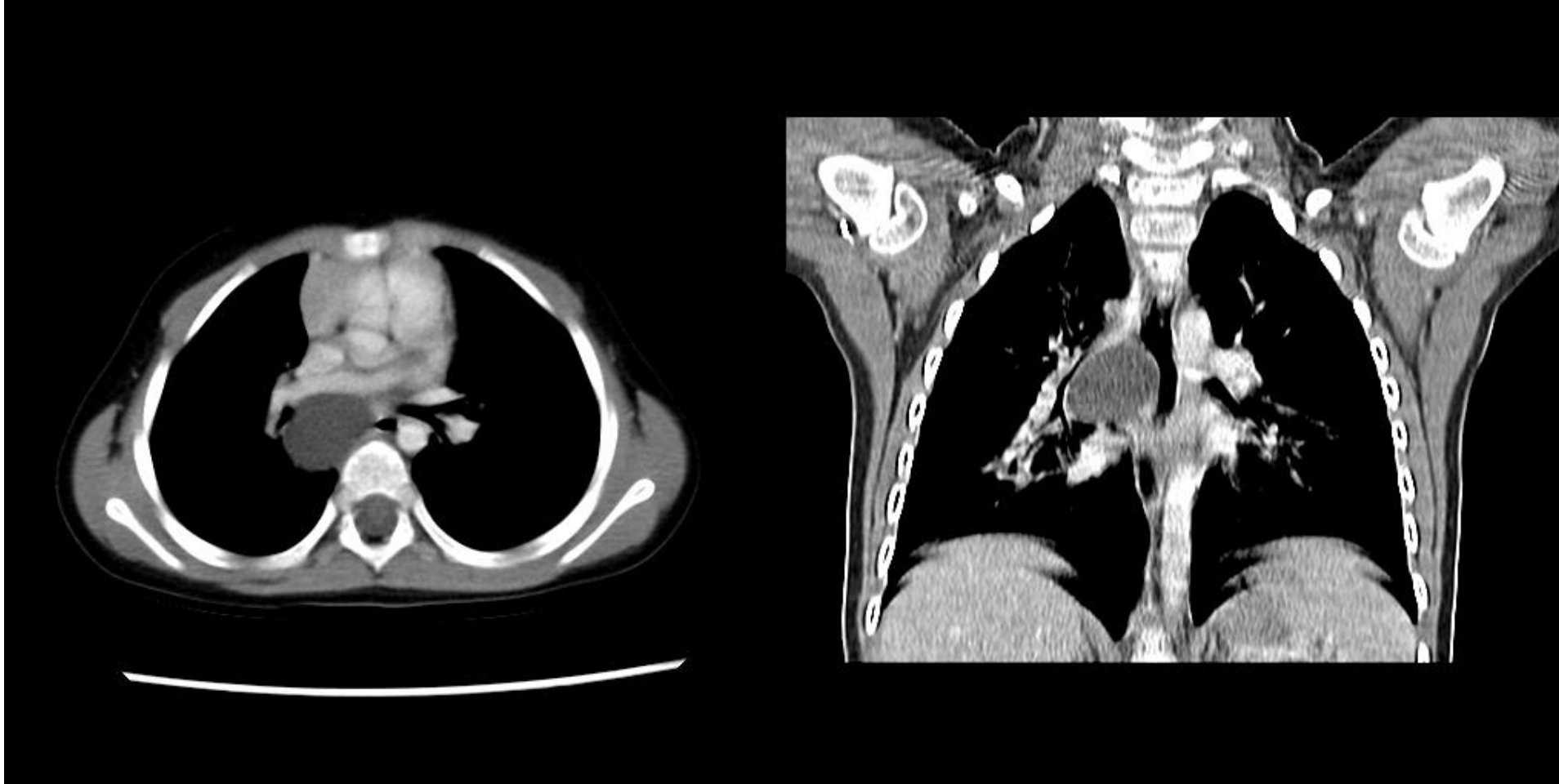
Courtesy Claire Langston
Previously published in
UpToDate

A large distended systemic artery is present at one border (red arrow). A dilated, mucus filled bronchus (blue arrow) is evident adjacent to the artery. The lung parenchyma has a microcystic appearance, distinguishing it from the adjacent normal parenchyma.



Microscopic examination of an intralobar pulmonary sequestration (ILS) demonstrates large, dilated airways containing numerous muciphages. The parenchyma shows small foci of lymphocytic infiltrates and is structurally abnormal, with thickened airspace walls and poorly subdivided airspaces.

Question 5



Question 5

You are evaluating a two year-old girl referred to your office for recurrent cough and wheeze. On examination, she has a fixed, low-pitched, monophonic wheeze. Initial chest radiograph findings result in a chest CT.

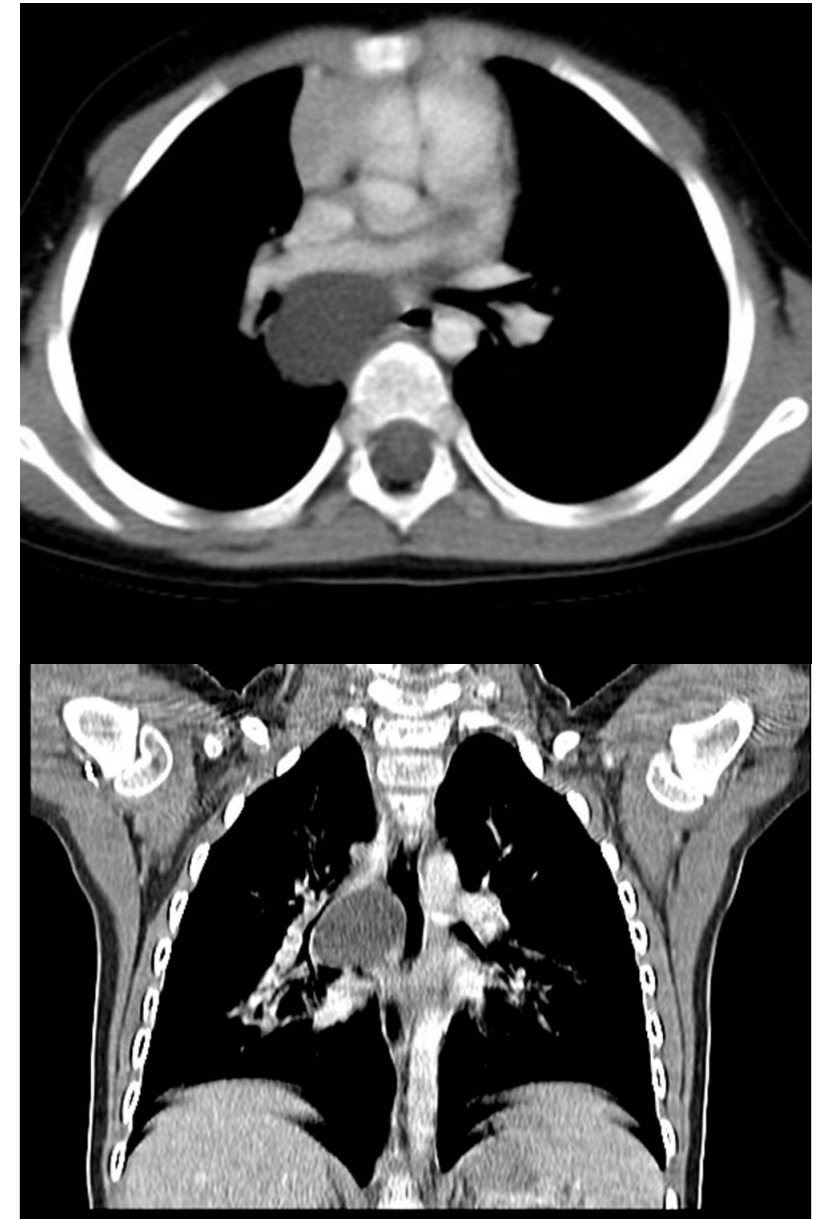
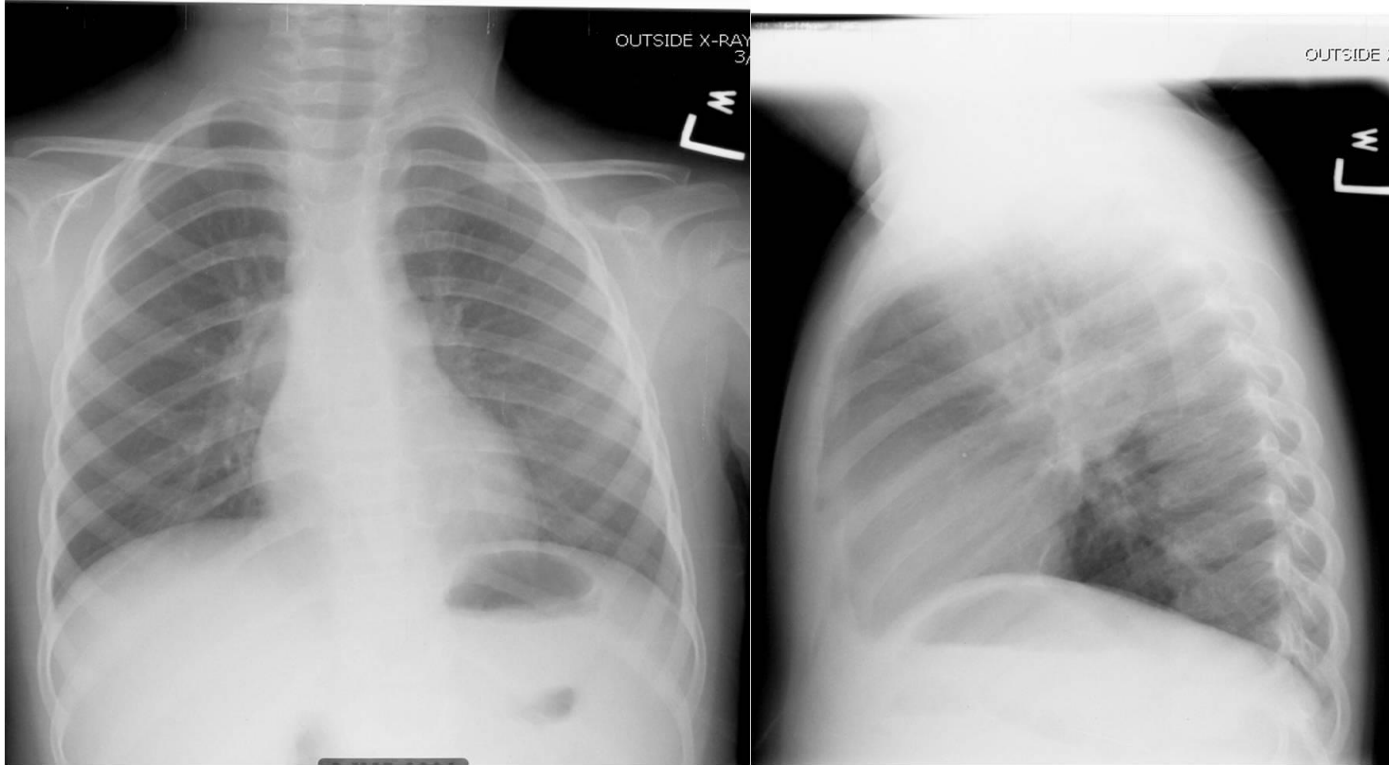
Your presumptive diagnosis based on the CT imaging is:

- A. Bronchogenic cyst**
- B. Congenital lobar emphysema
- C. Congenital pulmonary airway malformation
- D. Extra-lobar sequestration

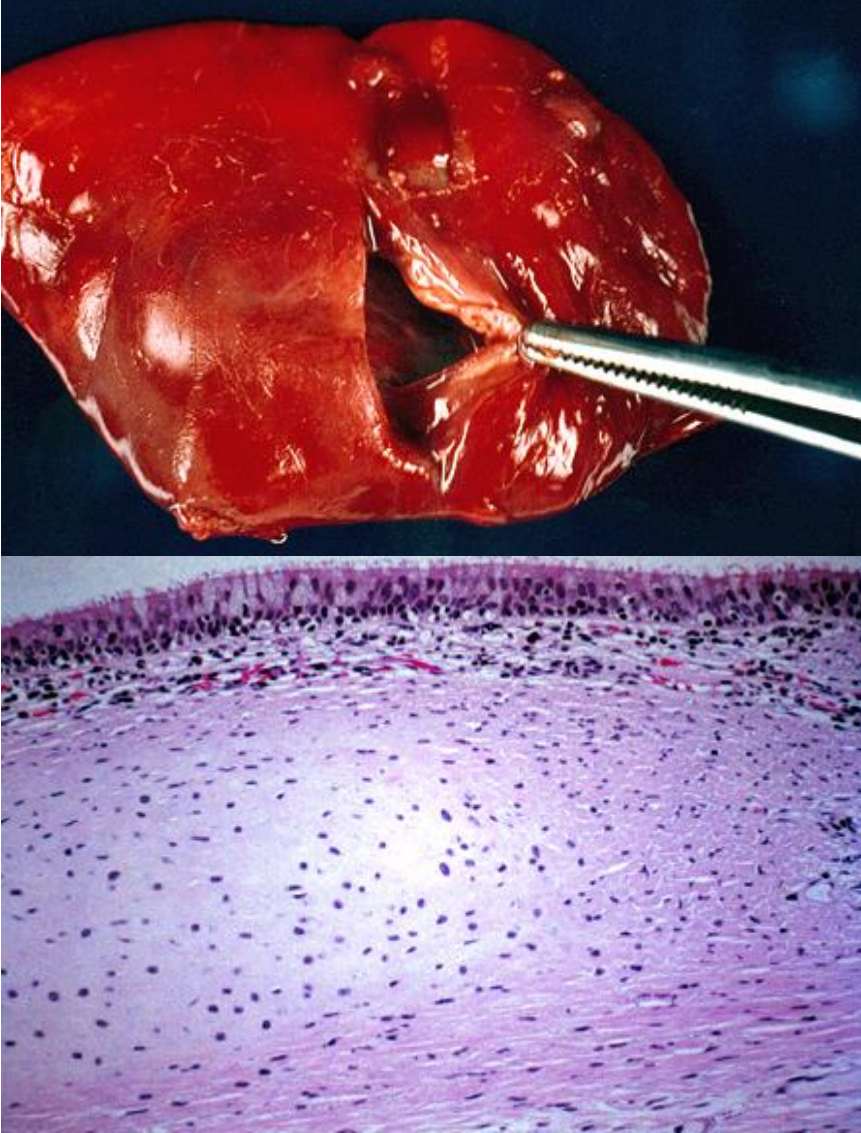
Bronchogenic Cyst

- Epidemiology
 - Incidence of 1 in 20,000
 - M:F = 1:1
 - May be identified on prenatal ultrasound through adulthood
- Pathophysiology
 - Fluid filled cysts lined with respiratory epithelium; cartilage plates; gastric mucosa
 - No connection to airways
 - $\frac{2}{3}$ mediastinal; $\frac{1}{3}$ parenchymal

- Clinical Characteristics
 - Symptoms develop from birth to adulthood
 - Respiratory compromise if large; recurrent cough, “wheeze”, infection, hemorrhage
 - Associated anomalies are generally not present
 - Diagnosis often possible on simple chest imaging
- Management and Prognosis
 - Resection is generally recommended as most develop complications



Courtesy Neil Mardis



The wall of the cyst has features of respiratory epithelium and contains cartilage and smooth muscle typical of a bronchus. The finding of cartilage plates is essential for the diagnosis.

Courtesy Claire Langston
Previously published in
UpToDate

Question 6

You have been asked to join the CDH Long Term Follow Up Clinic operated by your Division of Neonatology (which earns them a point on the US News and World Report Pediatric Hospital Survey).

In reviewing the literature, you find that which of the following is true:

- A. Chest radiographs in CDH generally demonstrate complete opacification of the involved side
- B. Morgagni hernias are most common
- C. Most CDH are left sided
- D. There is a strong male predominance

Question 6

You have been asked to join the CDH Long Term Follow Up Clinic operated by your Division of Neonatology (which earns them a point on the US News and World Report Pediatric Hospital Survey).

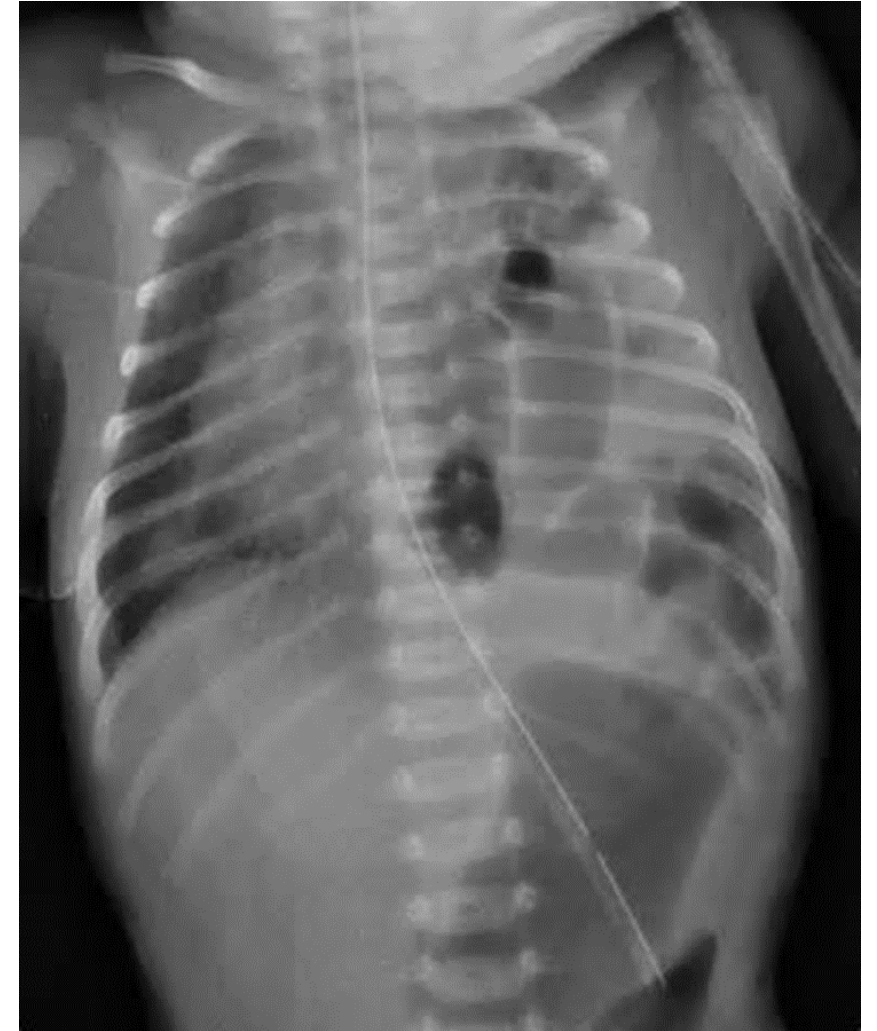
In reviewing the literature, you find that which of the following is true:

- A. Chest radiographs in CDH generally demonstrate complete opacification of the involved side
- B. Morgagni hernias are most common
- C. **Most CDH are left sided**
- D. There is a strong male predominance

Congenital Diaphragmatic Hernia

- Epidemiology
 - Incidence of 1 in 2,500-5,000
 - M = F
- Pathophysiology
 - Discontinuity of diaphragm allowing migration of abdominal viscera into thorax
 - Posterolateral (Bochdalek 95%), anterior (Morgagni 5%)
 - 80-85% left-sided; 10-15% right-sided
 - Pulmonary hypoplasia and pulmonary arterial muscular hyperplasia

- Clinical Characteristics
 - Respiratory distress and cyanosis
 - Barrel chest and scaphoid abdomen
 - Diagnosis generally possible on simple chest radiography
 - 50% with associated abnormalities



- Management and Prognosis
 - Fetal interventions (tracheal occlusion)
 - Postnatal management
 - Intubation and ventilation
 - ECMO
 - Stabilization then surgery
 - Long term issues
 - Pulmonary hypoplasia and pulmonary hypertension
 - Associated abnormalities

Question 7

The most common configuration of esophageal atresia and trachea-esophageal fistula is:

- A. EA with distal TEF
- B. EA with proximal TEF
- C. EA with proximal and distal TEFs
- D. H-type TEF without EA

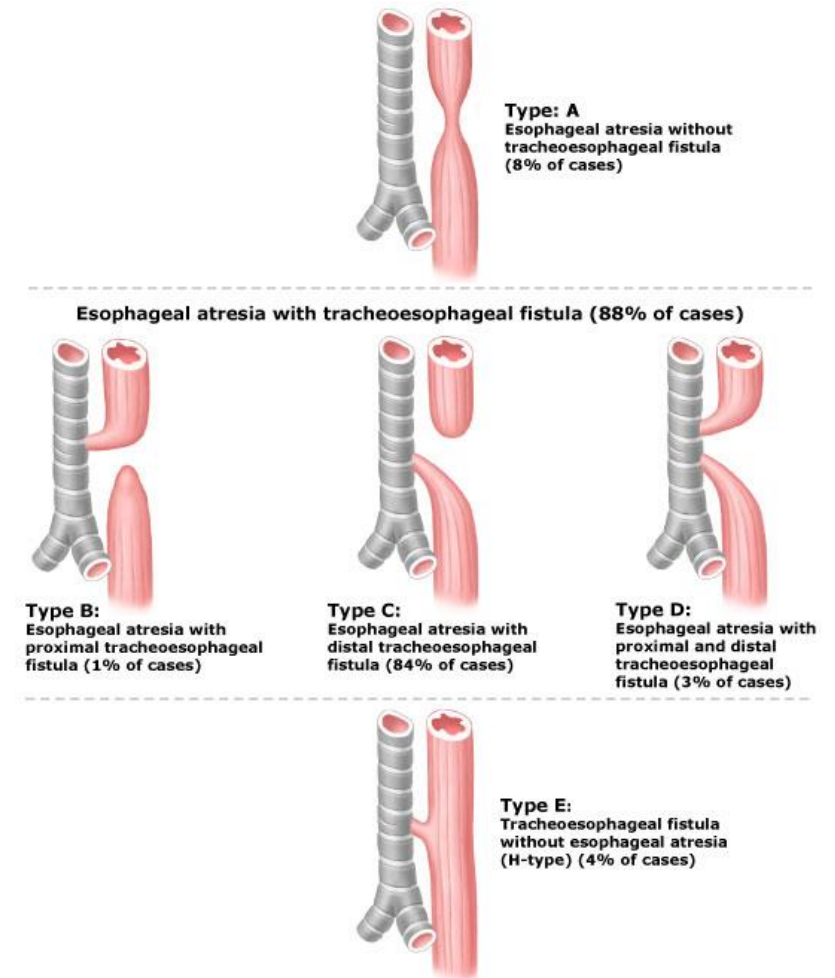
Question 7

The most common configuration of esophageal atresia and trachea-esophageal fistula is:

- A. EA with distal TEF
- B. EA with proximal TEF
- C. EA with proximal and distal TEFs
- D. H-type TEF without EA

Esophageal Atresia with Tracheoesophageal Fistula

- Epidemiology
 - 1:3500
 - M = F
- Pathophysiology
 - Abnormal septation of foregut
 - Four types with proximal EA and distal TEF accounting for almost 85%
 - Significant esophageal dysmotility and tracheomalacia



Clark, DC. Am Fam Physician
1999;59:910.

- Clinical Features

- Dysphagia and choking early with chronic cough and recurrent pneumonia later in life
- Diagnosis
 - Inability to pass gastric catheter
 - Contrast studies
 - Prone, retrograde, Trendelenburg esophagram
- 50% with associated abnormalities (CHARGE, VACTERL)

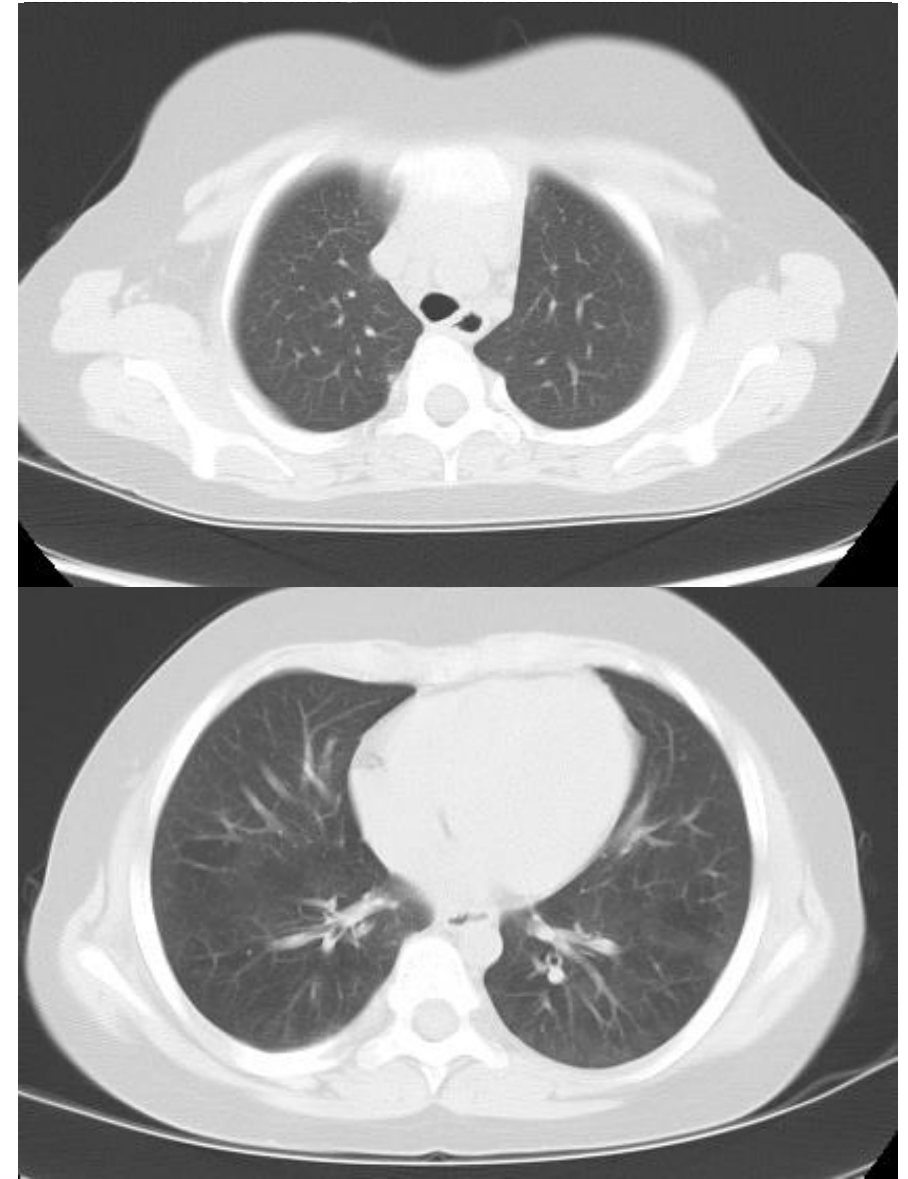- Management and Prognosis

- Initial management

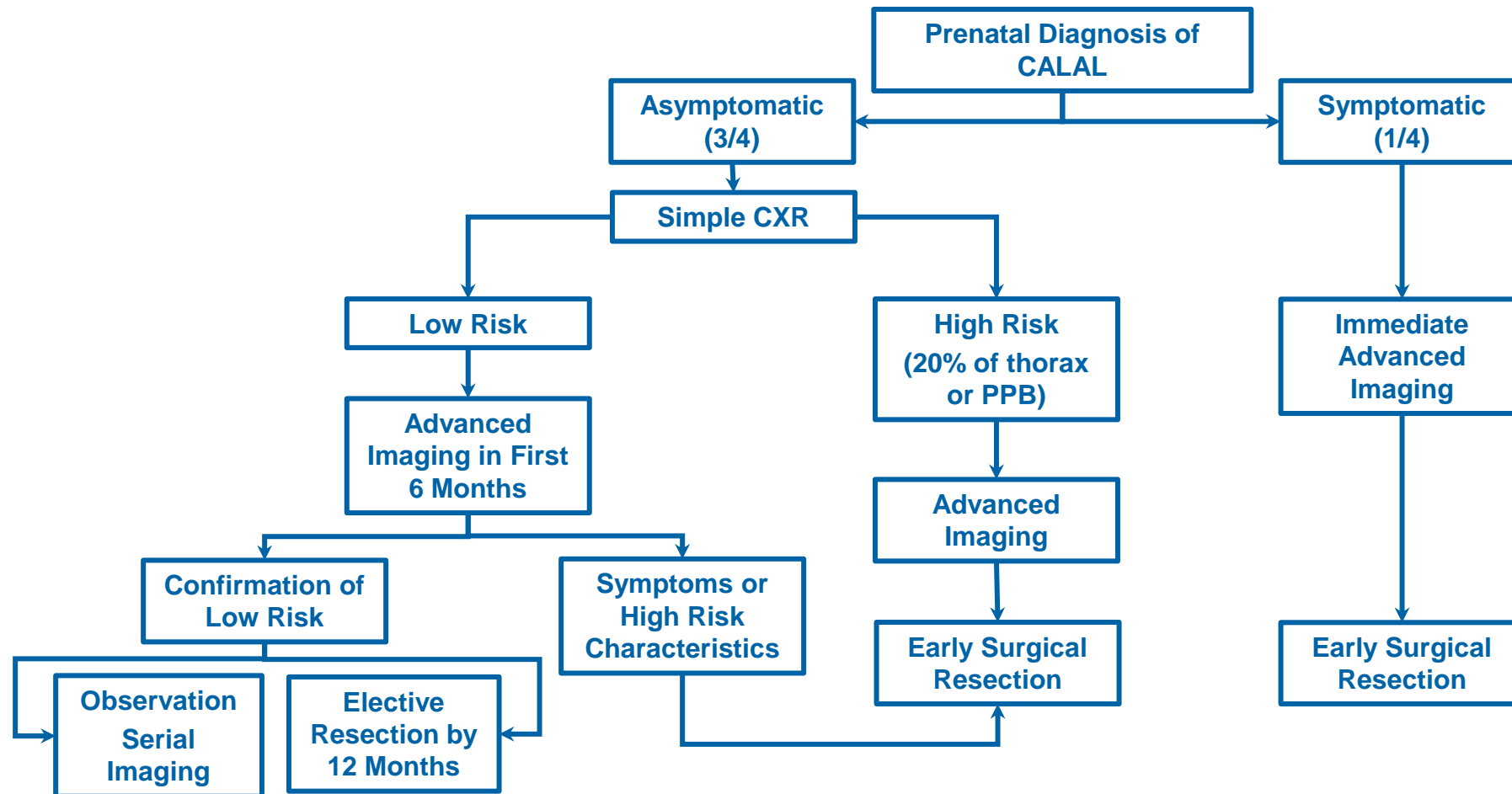
- Esophageal repair
 - Fistula ligation

- Long term problems

- Esophageal dysmotility with recurrent aspiration
 - Tracheomalacia



MANAGEMENT ALGORITHM



UpToDate. 2015

Summary

- Most CALAL are identified on prenatal ultrasound but have an extremely variable natural history
- All CALAL require advanced postnatal imaging by age 6 months
- Although controversial, most authorities recommend resection for most CALAL
 - Small ELS and asymptomatic CLE may be observed

- Prognosis for most CALAL is very good after resection or repair
 - CALAL associated with other congenital abnormalities may have worse prognosis
 - CPAM associated with PPB have a more guarded prognosis
 - CDH prognosis largely dependent on degree of pulmonary hypoplasia
 - TEF associated with dysphagia and tracheomalacia

Thank You!

Questions?