

Children's Mercy Kansas City

SHARE @ Children's Mercy

Manuscripts, Articles, Book Chapters and Other Papers

12-1-2006

Guidelines and standards for performance of a pediatric echocardiogram: a report from the Task Force of the Pediatric Council of the American Society of Echocardiography.

Wyman W. Lai

Tal Geva

Girish S. Shirali

Children's Mercy Hospital

Peter C. Frommelt

Richard A. Humes

See next page for additional authors

Let us know how access to this publication benefits you

Follow this and additional works at: <https://scholarlyexchange.childrensmercy.org/papers>



Part of the [Cardiology Commons](#), [Cardiovascular System Commons](#), [Investigative Techniques Commons](#), and the [Pediatrics Commons](#)

Recommended Citation

Lai, W. W., Geva, T., Shirali, G. S., Frommelt, P. C., Humes, R. A., Brook, M. M., Pignatelli, R. H., Rychik, J., . Guidelines and standards for performance of a pediatric echocardiogram: a report from the Task Force of the Pediatric Council of the American Society of Echocardiography. *Journal of the American Society of Echocardiography : official publication of the American Society of Echocardiography* 19, 1413-1430 (2006).

This Article is brought to you for free and open access by SHARE @ Children's Mercy. It has been accepted for inclusion in Manuscripts, Articles, Book Chapters and Other Papers by an authorized administrator of SHARE @ Children's Mercy. For more information, please contact hlsteel@cmh.edu.

Creator(s)

Wyman W. Lai, Tal Geva, Girish S. Shirali, Peter C. Frommelt, Richard A. Humes, Michael M. Brook, Ricardo H. Pignatelli, Jack Rychik, and Pediatric Council of the American Society of Echocardiography

Guidelines and Standards for Performance of a Pediatric Echocardiogram: A Report from the Task Force of the Pediatric Council of the American Society of Echocardiography

Wyman W. Lai, MD, MPH, FASE, Tal Geva, MD, FASE, Girish S. Shirali, MD, Peter C. Frommelt, MD, Richard A. Humes, MD, FASE, Michael M. Brook, MD, Ricardo H. Pignatelli, MD, and Jack Rychik, MD, Writing Committee, *New York, New York; Boston, Massachusetts; Charleston, South Carolina; Milwaukee, Wisconsin; Detroit, Michigan; San Francisco, California; Houston, Texas; and Philadelphia, Pennsylvania*

Echocardiography has become the primary imaging tool in the diagnosis and assessment of congenital and acquired heart disease in infants, children, and adolescents. Transthoracic echocardiography (TTE) is an ideal tool for cardiac assessment, as it is noninvasive, portable, and efficacious in providing detailed anatomic, hemodynamic, and physiologic information about the pediatric heart.

Recommendations for standards in the performance of a routine 2-dimensional (2D) echocardiogram,¹ fetal echocardiogram,² pediatric transesophageal echocardiogram,³ intraoperative transesophageal echocardiogram,⁴ and stress echocardiogram⁵ exist, as do guidelines for appropriate training in various echocardiographic disciplines.⁶⁻¹² As part of the accreditation process for echocardiography laboratories, the Intersocietal Commission for the Accreditation of Echocardiography Laboratories has established basic performance standards for pediatric TTE,¹³ but no other standards document exists for the performance of a pediatric TTE.

The pediatric echocardiogram is a unique examination with features that distinguish it from other echocardiograms. There is a wide spectrum of anomalies encountered in patients with congenital heart disease. Certain views are of added importance

for pediatric examinations: the subxiphoid (or subcostal), suprasternal notch, and right parasternal views. The acquisition and proper display of images from these views are critical aspects of the pediatric TTE. In addition, special techniques are required for imaging uncooperative infants and young children, including sedation and distraction tools that will allow performance of a complete examination.

The purposes of this document are to: (1) describe indications for pediatric TTE; (2) define optimal instrumentation and laboratory setup for pediatric echocardiographic examinations; (3) provide a framework of necessary knowledge and training for sonographers and physicians; (4) establish an examination protocol that defines necessary echocardiographic windows and views; (5) establish a baseline list of recommended measurements to be performed in a complete pediatric echocardiogram; and (6) discuss reporting requirements and formatting of pediatric reports.

INDICATIONS

Knowledge of indications for an echocardiogram is important to obtain the information required for the diagnosis and proper treatment of the pediatric patient. The general categories of indications are provided below, with emphasis placed on the indications for a pediatric echocardiogram versus a standard adult study. For detailed age-specific lists of indications, the reader is referred to prior published guidelines.¹⁴

Children with suggested or known heart disease frequently require serial studies to evaluate the evolution or progression of heart disease. Serial studies may be indicated at routine intervals for monitoring of valve function, growth of cardiovascular structures, ventricular function, and potential sequelae of medical or surgical intervention.¹⁵⁻¹⁸

From the Mount Sinai Medical Center, New York (W.W.L.); Children's Hospital, Boston (T.G.); Medical University of South Carolina, Charleston (G.S.S.); Children's Hospital of Wisconsin, Milwaukee (P.C.F.); Children's Hospital of Michigan, Detroit (R.A.H.); University of San Francisco (M.M.B.); Texas Children's Hospital, Houston (R.H.P.); and Children's Hospital of Philadelphia (J.R.).

Reprint requests: Wyman W. Lai, MD, MPH, FASE, Division of Pediatric Cardiology, Box 1201, Mount Sinai Medical Center, One Gustave L. Levy Place, New York, NY 10029 (E-mail: wym.lai@mssm.edu).

J Am Soc Echocardiogr 2006;19:1413-1430.

0894-7317/\$32.00

Copyright 2006 by the American Society of Echocardiography.

doi:10.1016/j.echo.2006.09.001

Congenital Heart Disease: History, Symptoms, and Signs

Indications for the performance of a pediatric echocardiogram span a wide range of symptoms and signs, including cyanosis, failure to thrive, exercise-induced chest pain or syncope, respiratory distress, murmurs, congestive heart failure, abnormal arterial pulses, or cardiomegaly. These may suggest categories of structural congenital heart disease including intracardiac left-to-right or right-to-left shunts, obstructive lesions, regurgitant lesions, transposition physiology, abnormal systemic or pulmonary venous connections, conotruncal anomalies, coronary artery anomalies, functionally univentricular hearts, and other complex lesions, including abnormal laterality (heterotaxy/isomerism). Certain syndromes, family history of inherited heart disease, and extracardiac abnormalities that are known to be associated with congenital heart disease constitute clinical scenarios for which echocardiography is indicated even in the absence of specific cardiac symptoms and signs. Abnormalities on other tests such as fetal echocardiography, chest radiograph, electrocardiogram, and chromosomal analysis constitute another group in which the suggestion of congenital heart disease is addressed specifically by echocardiography.

Acquired Heart Diseases and Noncardiac Diseases

An echocardiogram is indicated for the evaluation of acquired heart diseases in children, including Kawasaki disease, infective endocarditis, all forms of cardiomyopathies, rheumatic fever and carditis, systemic lupus erythematosus, myocarditis, pericarditis, HIV infection, and exposure to cardiotoxic drugs. Pediatric echocardiography is indicated in the assessment of potential cardiac or cardiopulmonary transplant donors and transplant recipients. Recently, echocardiography has been recommended in all children who are newly diagnosed with systemic hypertension.¹⁹ Noncardiac disease states that affect the heart such as pulmonary hypertension constitute an important indication for serial pediatric echocardiograms. Echocardiography may also be indicated in children with thromboembolic events, indwelling catheters and sepsis, or superior vena cava syndrome.

Arrhythmias

Children with arrhythmias may have underlying structural cardiac disease such as congenitally corrected transposition or Ebstein's anomaly of the tricuspid valve, which may be associated with subtle clinical findings and are best evaluated using echocardiography. Sustained arrhythmias or antiarrhythmic medications may lead to functional perturbations of the heart that may only be detectable by

echocardiography and have important implications for management.

INSTRUMENTATION, PATIENT PREPARATION, AND PATIENT SAFETY

Instrumentation

Ultrasound instruments used for diagnostic studies should include, at a minimum, hardware and software to perform M-mode, 2D imaging, color flow mapping, and spectral Doppler studies, including pulsed wave and continuous wave capabilities. The transducers used in pediatric studies should provide adequate imaging across the wide range of depths encountered in pediatric cases. Multiple imaging transducers, ranging from low frequency (2-2.5 MHz) to high frequency (≥ 7.5 MHz), should be available; a multifrequency transducer that includes all these frequencies is also an option. A transducer dedicated to the performance of continuous wave Doppler studies should also be available for each study.

The video screen and display should be of suitable size and quality for observation and interpretation of all the above modalities. The display should identify the parent institution, a patient identifier, and the date and time of the study. The electrocardiogram should also be displayed in real time with the echocardiographic signal. Range or depth markers should be available on all displays. Measurement capabilities must be present to allow measurement of the distance between two points, an area on a 2D image, blood flow velocities, time intervals, and peak and mean gradients from spectral Doppler studies.

Data Acquisition and Storage

Echocardiographic studies must be recorded and stored as moving images and must be stored on a medium that allows for playback of the recorded moving images. This would include videotape or digital recording media. It is unacceptable to store or archive moving echocardiographic images on a medium that displays only a static image, such as recording film or paper. Portions of the echocardiographic examination such as M-mode frames and Doppler spectral measurements may be displayed and recorded as a static image on media appropriate to the laboratory situation.

Patient Preparation and Safety

Sufficient time should be allotted for each study according to the procedure type. The performance time of an uncomplicated, complete (imaging and Doppler) pediatric TTE examination is generally 45 to 60 minutes (from patient encounter to departure). Additional time may be required for complicated studies. All procedures should be explained to the patient and/or

parents or guardians before the onset of the study. The patient should be placed in a reclining position in a comfortable environment. A darkened room is preferable for the performance of the study. Appropriate pillows and blankets should be used for patient comfort and privacy. The sonographic gel should be warmed to body temperature before the start of the examination. It is recommended that appropriate distractions be provided in echocardiographic laboratories performing studies on preschool children. These may include toys, games, television, or movies. A parent or guardian should accompany all children during the echocardiographic study except where privacy issues supersede.

The laboratory should recognize the potential need for sedation of pediatric patients to obtain an adequate examination. Written policies including, but not limited to, the type of sedatives, appropriate dosing for age and size, and proper monitoring of children during and after the examination should exist for the use of conscious sedation in children.^{20,21}

Each laboratory should have a written procedure in place for handling acute medical emergencies in children. This should include a fully equipped cardiac arrest cart (crash cart) and other necessary equipment for responding to medical emergencies in pediatric patients of all sizes.

SKILLS AND KNOWLEDGE

Echocardiography of congenital and acquired pediatric heart disease is an operator-dependent imaging technique that requires high levels of technical and interpretive skills to maximize its diagnostic accuracy. Specialized training is required in the assessment of cardiovascular malformations to determine treatment options and to assess outcomes after an ever-increasing number of interventional and surgical procedures.

Physicians

Because TTE is the primary diagnostic imaging modality in children with heart disease, pediatric cardiologists must possess basic skills in performance and interpretation of transthoracic cardiac ultrasound, including M-mode, 2D imaging, and various Doppler methods. Physicians who specialize in echocardiography of pediatric heart disease undergo extended training in this domain.

This committee reviewed and considered existing guidelines for training in pediatric echocardiography.^{8,22-24} The American College of Cardiology (ACC) Pediatric Cardiology/Congenital Heart Disease Committee and the ACC Training Program Directors Committee have jointly developed new recommendations for training in pediatric cardiol-

ogy. The recommendations in the ACC/American Heart Association/American Academy of Pediatrics Clinical Competency and Training Statement on Pediatric Cardiology (Task Force 2: Pediatric Training Guidelines for Noninvasive Cardiac Imaging) represent the most recent guidelines and, with minor modifications, are incorporated in this document.²⁵

Levels of expertise. Physicians who practice TTE may have one of two levels of expertise, core or advanced. The core level includes the basic set of technical and interpretive skills required for graduation from a pediatric cardiology training program accredited by ACGME. Physicians with this level of expertise are expected to be able to perform and interpret TTEs in normal infants, children, and adolescents, and in those with childhood heart disease with consultation as needed. "Advanced" is a high level of expertise in all aspects of pediatric echocardiography. Physicians with this level of training are expected to be able to perform independently and to interpret echocardiograms in patients with all forms of congenital and acquired pediatric heart disease, and to supervise and train others.

Table 1 outlines the required knowledge for the core and advanced levels of expertise, and **Table 2** delineates the required skills. **Table 3** outlines the training methods recommended for the two levels of expertise.

Evaluation of knowledge and skills. Unlike adult echocardiography, there is currently no formal test that can be used to examine competency in pediatric echocardiography in North America. The optimal evaluation of clinical competence is, therefore, based on assessment of the trainee's skills by the director of the pediatric echocardiography laboratory. Direct observation of the trainee during performance of echocardiograms provides information about imaging skills and understanding of the ultrasound instruments. The maintenance of a log of echocardiograms performed by each trainee is required. Conferences in which echocardiograms are presented provide an opportunity to assess skills in interpretation of images and Doppler recordings. Conferences may also be used to promote and evaluate skills in research design and methods, and teaching effectiveness. The laboratory director, in consultation with the teaching staff, should evaluate each trainee in writing on a regular basis.

Maintenance of knowledge and skills. Clinical competence in pediatric echocardiography requires continued practice of all forms of cardiac ultrasound techniques in an active program in which patients with a wide range of pediatric heart disease are seen. To maintain core-level competence, a minimum of 150 TTEs per year should be performed or interpreted. To maintain advanced-level competence, a minimum of 500 TTEs per year should be performed or interpreted. In addition, continued participation in intramural conferences and in continuing medical

Table 1 Required knowledge base for core and advanced levels of expertise

Level of expertise	Required knowledge base
Core	<ul style="list-style-type: none"> ● Understanding of the basic principles of ultrasound physics ● Knowledge of the indications for transthoracic echocardiography in pediatric patients ● Knowledge of common congenital heart defects and surgical interventions ● Knowledge of Doppler methods and their application for assessment of blood flow and prediction of intracardiac pressures ● Knowledge of the limitations of echocardiography and Doppler techniques ● Knowledge of alternative diagnostic imaging techniques ● Knowledge of standard acoustic windows and transducer positions ● Knowledge of image display and orientation used in pediatric echocardiography ● Ability to recognize normal and abnormal cardiovascular structures by 2-dimensional imaging and to correlate the cross-sectional images with anatomic structures ● Familiarity with standard echocardiographic methods of ventricular function assessment ● Familiarity with major developments in the field of noninvasive diagnostic imaging
Advanced	<p>In addition to the knowledge base required in the core level:</p> <ul style="list-style-type: none"> ● In-depth knowledge of ultrasound physics ● Ability to recognize and characterize rare and complex congenital and acquired cardiovascular abnormalities in a variety of clinical settings ● In-depth understanding of Doppler methods and their application to the assessment of cardiovascular physiology ● Familiarity with all echocardiographic methods available for assessment of global and regional ventricular function and knowledge of the strengths and weaknesses of these techniques ● Up-to-date knowledge of recent advances in the field of noninvasive cardiac imaging, including ability to review critically published research that pertains to the field ● Knowledge of current training guidelines and regulations relevant to pediatric echocardiography

Table 2 Required skills for core and advanced levels of expertise

Level of expertise	Required skills
Core	<ul style="list-style-type: none"> ● Ability to safely, properly, and efficiently use cardiac ultrasound equipment ● Ability to perform a complete transthoracic echocardiographic examination with proper use of M-mode, 2-dimensional, and Doppler techniques in normal pediatric patients and in those with heart disease, with consultation as needed
Advanced	<p>In addition to the skills required in the core level:</p> <ul style="list-style-type: none"> ● Ability to perform independently a complete transthoracic echocardiographic examination with proper use of all available ultrasound techniques in patients with all types of congenital heart disease ● Ability to assess cardiovascular physiology and global and regional ventricular function using a variety of ultrasound techniques ● Ability to supervise and teach pediatric echocardiography to sonographers, pediatric cardiology fellows, and other physicians

education activities related to advances in echocardiography is essential.

Sonographers

The committee reviewed and adopted guidelines published by the American Society of Echocardiography (ASE) in "Minimum Standards of Echocardiography (ASE) in "Minimum Standards for the Cardiac Sonographer: A Position Paper" regarding the competence of sonographers performing echocardiograms.²⁶ Separate credentialing requirements apply for sonographers in each area of subspecialization (ie, pediatric vs adult TTE). A summary of the guidelines is as follows.

The ASE believes that there are 3 primary elements involved in assuring the competence of a cardiac sonographer.

Credentialing and formal education. A cardiac sonographer must obtain a recognized credential within the time frame and using the pathways specified by a credentialing organization recognized by the ASE. A new cardiac sonographer entering the field must comply with the formal educational requirements specified by the applicable credentialing organization, and must fulfill those requirements through participation in a program recognized by the ASE.

Technical competence. A cardiac sonographer must demonstrate and document technical competence in the performance of those types of echocardiographic examinations that the sonographer performs.

Continuing education. A cardiac sonographer must maintain his or her skills through participation in appropriate continuing education.

Table 3 Training methods recommended for core and advanced levels of expertise

Level of expertise	Recommended methods of training
Core	<ul style="list-style-type: none"> ● Training should take place in a pediatric echocardiography laboratory that serves a hospital with an accredited pediatric cardiology program, inpatient and outpatient facilities, neonatal and pediatric intensive care departments, a pediatric cardiac catheterization laboratory, and a congenital heart surgery program ● Supervised performance of at least 150 transthoracic echocardiograms (at least 50 in infants age \leq 1 y)* ● Review at least 150 transthoracic echocardiograms with a qualified staff pediatric echocardiographer* ● Participate in didactic conferences in which echocardiographic data are reviewed and their clinical applications are discussed ● Reading of textbooks, review articles, and original research on pediatric echocardiography ● Attendance at CME courses that are either dedicated to or include pediatric echocardiography
Advanced	<p>In addition to the training methods described in the core level:</p> <ul style="list-style-type: none"> ● Perform at least 200 additional transthoracic echocardiograms (at least 50 in infants age \leq 1 y) with subsequent review and critique of the examinations by the responsible staff pediatric echocardiographer* ● Review at least 200 additional transthoracic echocardiograms with a qualified staff pediatric echocardiographer* ● Trainees should gradually attain a high level of independence; the degree and rate at which independence is attained should be determined by the director of the laboratory ● Prepare and present echocardiographic data at clinical and didactic conferences ● Active participation in research that involves echocardiography of pediatric heart disease

CME, Continuing medical education.

*The recommended numbers of examinations outlined here represent minimal and not optimal requirements.

EXAMINATION PROTOCOL

Examination Principles

Although laboratory protocols vary, the basic elements of a standard examination involve 2D images supplemented by Doppler and color Doppler information in multiple orthogonal imaging planes. The studies are organized by acoustic windows from which the heart is examined. The information may be recorded in complete sweeps, multiple selected single planes, or with a combination of both techniques.²⁷⁻²⁹ A complete examination protocol should outline all views to be obtained, including their preferred order, the imaging modalities to be deployed for each view, and the preferred methods for recording and display. A list of the structures to be examined with each view is helpful, and the required versus optional measurements should be clearly defined.

Many pediatric echocardiography laboratories begin the examination with subxiphoid, or subcostal, imaging instead of left parasternal views. This allows for the determination and display of visceral situs (site or location) at the beginning of an examination. Regardless of where the examination starts, the segmental approach is used to describe all of the major cardiovascular structures in sequence.^{30,31} An abnormal finding, either structural or hemodynamic, must be fully examined. Quantification of ventricular function is often an important part of the examination.

For a pediatric echocardiogram, by convention, the anterior and superior structures are displayed at the top of the video screen, and the rightward

structures are generally placed on the left side of the image display. Therefore, the preferred method of display is with the image apex “inverted,” with the image apex at the bottom of the video screen, during subxiphoid and apical imaging to demonstrate structures in their correct anatomic orientation. This is important because of the wide range of anatomic variations frequently seen in patients with congenital heart disease. The one exception to the left-right rule of orientation is the parasternal long-axis view, in which the apex of the heart is displayed on the left side of the video screen in both levocardia and dextrocardia.

The diagnostic accuracy of an examination depends greatly on the image quality. Technical adjustments must be made by the operator to improve signal-to-noise ratio and image resolution. The appropriate probe and optimal transducer frequency are selected to image the structures in question, and adjustments of the electronic (acoustic) focus depth are made throughout the study as necessary. Centering of structures of interest, using an appropriate degree of magnification, and optimizing of windows for imaging and Doppler interrogation are critical for image quality. Patient position, comfort, and level of anxiety are important considerations throughout the examination.

As a pediatric echocardiogram is progressing, the sonographer or echocardiographer must keep in mind the indications for the study and the need to address issues that may affect treatment as they arise. A complete examination may require that custom, or in-between, planes be used to investigate or display an abnormality. Whatever method of recording or display is selected as the laboratory

standard, complete sweeps of the heart should be made during the examination to rule out abnormalities at its base or apex or on one of its surfaces. In addition, the major vascular structures must be evaluated as part of a complete examination.

Extracardiac structures are visualized during a standard TTE examination. Mediastinal abnormalities such as masses and cysts, if present, should be noted. Careful attention to symmetry and amplitude of diaphragm motion and screening for pleural effusions from subxiphoid and flank windows is particularly important in postoperative cardiac cases.

Multiple Orthogonal Imaging Planes

The standard views of a 2D echocardiogram, as defined early on by the ASE,³² are all used as part of a pediatric echocardiogram. In addition, there are imaging planes that are more commonly associated with a routine pediatric study: subxiphoid (subcostal), suprasternal notch, and right sternal border. These imaging planes provide unique information regarding cardiovascular malformations that are often seen in childhood. A complete examination requires that the cardiovascular structures be imaged from multiple orthogonal planes. This practice minimizes artifacts caused by false dropout of structures imaged parallel to the beam of interrogation or shadowing from reflective structures proximal to the area of interest.

The imaging planes are identified by transducer location (subxiphoid, apical, parasternal, suprasternal notch, and right parasternal) and by the plane of examination relative to the heart (4-chamber, 2-chamber, long-axis, and short-axis). In addition, imaging planes may be described as anatomic planes (sagittal, parasagittal, transverse, or coronal).

The views and structures presented below are described as seen in a patient with normal or near-normal cardiovascular anatomy. Table 4 lists the structures that should be visualized from the standard examination views.

Subxiphoid (subcostal) views. Subxiphoid imaging^{33,34} begins with the determination of abdominal visceral situs in the transverse plane. In addition to visualization of the liver and stomach, the spleen should be sought in patients with abnormal abdominal visceral situs. The location of the hepatic segment of the inferior vena cava and descending aorta in relation to the midline and one another are then determined. As the plane of imaging is angled from the abdomen to the thorax, the connections of the hepatic veins to the inferior vena cava are visualized, followed by the connection of the inferior vena cava to the right atrium. The patency of the inferior vena cava should be documented; if a dilated azygos vein is seen posterior to the descending aorta, interruption of inferior vena cava should be suspected. The

Table 4 Structures viewed from standard examination views

Subxiphoid (subcostal) views	Left parasternal views
Inferior vena cava	Inferior vena cava
Hepatic veins	Superior vena cava
Abdominal aorta	Left atrium
Diaphragm	Right atrium
Superior vena cava	Atrial septum
Left atrium	Coronary sinus
Right atrium	Pulmonary veins
Atrial septum	Mitral valve
Coronary sinus	Tricuspid valve
Pulmonary veins	Left ventricle
Mitral valve	Right ventricle
Tricuspid valve	Ventricular septum
Left ventricle	Left ventricular papillary muscles
Right ventricle	Aortic valve
Ventricular septum	Pulmonary valve
Left ventricular papillary muscles	Ascending aorta
Aortic valve	Coronary arteries
Pulmonary valve	Main and branch pulmonary arteries
Ascending aorta	Pericardium
Coronary arteries	
Main and branch pulmonary arteries	Suprasternal notch views
Pericardium	Superior vena cava
	Left atrium
	Pulmonary veins
	Ascending aorta
	Superior thoracic aorta
Apical views	Main and branch pulmonary arteries
Inferior vena cava	Aortic arch
Left atrium	Proximal brachiocephalic arteries
Right atrium	Left innominate vein
Atrial septum	
Coronary sinus	Right parasternal views
Selected pulmonary veins	Inferior vena cava
Mitral valve	Superior vena cava
Tricuspid valve	Right atrium
Left ventricle	Atrial septum
Right ventricle	Right pulmonary veins
Ventricular septum	Ascending aorta
Left ventricular papillary muscles	Right pulmonary artery
Aortic valve	
Pulmonary valve	
Ascending aorta	
Main and branch pulmonary arteries	

descending aorta at the level of the diaphragm should be interrogated by Doppler. Any additional vascular structures crossing the diaphragm should be fully investigated.

The subxiphoid long-axis sweep (Figure 1) begins in the transverse plane and passes the inferior/posterior surface of the heart, which includes the coronary sinus. The position of the left coronary ostium is well visualized as the ascending aorta is imaged. The posterior descending coronary artery may be seen in the posterior interventricular groove. The long-axis view allows for good visualization of

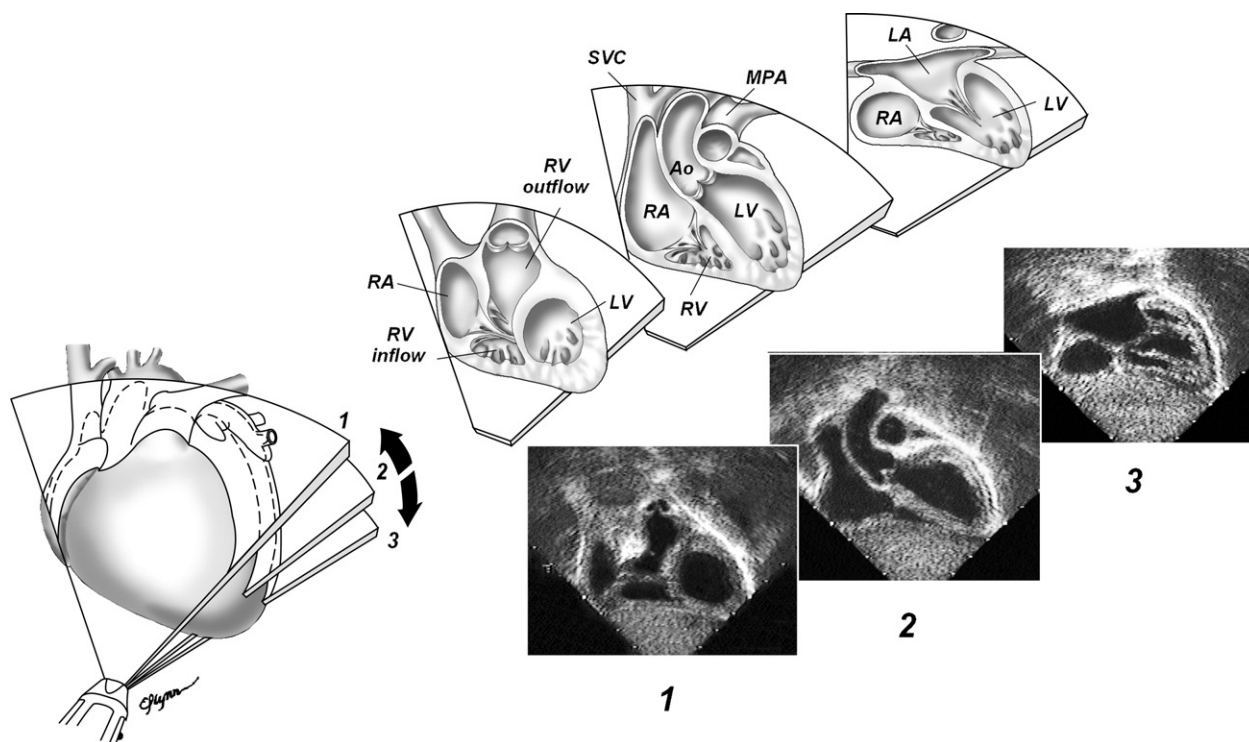


Figure 1 Subxiphoid long-axis views demonstrated in sweep from nearly coronal plane back toward transverse plane. 1, Right ventricular (RV) inflow and outflow are seen with pulmonary valve. 2, With inferior angulation, long axis of left ventricle (LV), aortic (Ao) valve, and ascending Ao are seen. Superior vena cava (SVC) is seen to right of ascending Ao, and main pulmonary artery (MPA) is seen to left. Connection of SVC to right atrium (RA) is demonstrated. 3, As transducer is angled back toward abdomen, atrial septum and pulmonary venous connections to left atrium (LA) are viewed. (Reproduced with permission from: Geva T. Echocardiography and Doppler ultrasound. In: Garson A, Bricker JT, Fisher DJ, Neish SR, editors. The science and practice of pediatric cardiology. Baltimore: Williams and Wilkins; 1997, p. 789-843).

the atrial septum and color Doppler mapping of the anterior muscular septum.

The subxiphoid short-axis sweep (Figure 2) starts in a parasagittal plane that includes the inferior and superior venae cavae. Imaging normally begins to the right, allowing visualization of the right upper pulmonary vein as it passes lateral and posterior to the superior vena cava and then proceeds from the base to the apex of the heart. The transducer position may need to be repositioned (generally more rightward) during the sweep to maintain a short-axis imaging plane as the apex of the heart is visualized.

Apical views. Standard apical³⁵ 4-chamber and long-axis (3-chamber)-and, in some laboratories, apical 2-chamber-views are obtained. The apical 4-chamber view (Figure 3) includes a sweep that begins posteriorly to demonstrate the coronary sinus and the entrance of the inferior vena cava into the right atrium. The sweep ends at the anterior surface of the heart after passing through the 5-chamber view demonstrating the left ventricular

(LV) outflow tract (OT) and ascending aorta. The apical muscular septum may also be magnified in the 4-chamber view for color Doppler interrogation.

Repositioning of the transducer medially toward the lower left sternal border brings the right ventricular (RV) inflow and RV free wall more into alignment with the beam of interrogation. Superior and anterior angulation from this position brings the RV OT into alignment and often offers an optimal angle for Doppler interrogation of the RV OT.

Imaging of the LV OT (LVOT) from the apex allows for visualization of subaortic structures oriented perpendicular to the plane of insonation. The apical long-axis (3-chamber) view (Figure 4) allows for optimal Doppler interrogation of the LVOT and ascending aorta. Modified views foreshortening the LV may allow clearer visualization of the LVOT. Apical 2-chamber views are used primarily for assessment of global ventricular function or regional wall motion.

Parasternal (left parasternal) views. The transducer in the parasternal^{36,37} long-axis view (Figure

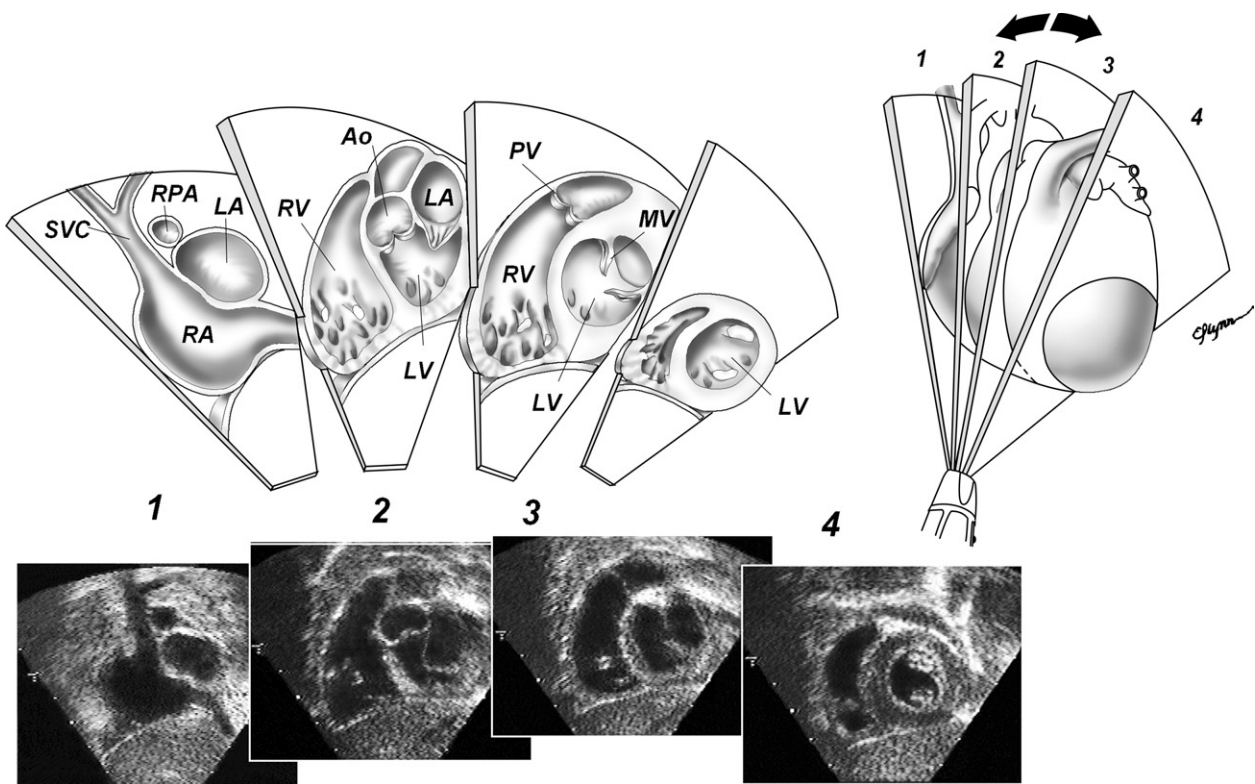


Figure 2 Subxiphoid short-axis views. 1, At rightward aspect of heart, superior vena cava (SVC) and inferior vena cava enter right atrium (RA). Right pulmonary artery (RPA) is seen in cross section behind SVC and above left atrium (LA). 2, With leftward angulation, base of left ventricle (LV) and right ventricle (RV) and atrioventricular valves are seen. Aortic (Ao) valve is seen in cross section at this level. 3, Further leftward angulation reveals cross-sectional view of LV and mitral valve (MV), and RV outflow tract and pulmonary valve (PV). 4, Sweep then passes through midmuscular septum and LV papillary muscles toward apical portions of both ventricles. (Reproduced with permission from: Geva T. Echocardiography and Doppler ultrasound. In: Garson A, Bricker JT, Fisher DJ, Neish SR, editors. The science and practice of pediatric cardiology. Baltimore: Williams and Wilkins; 1997, p. 789-843).

5) is positioned over the LVOT, allowing visualization of the aortic and mitral valves. The long-axis sweep includes the RV inflow and outflow. The long-axis or modified parasagittal view of the aorta best demonstrates the position of the right coronary artery ostium relative to the sinotubular junction. The parasternal short-axis view (Figure 6) at the base of the heart can provide detailed imaging of aortic valve morphology and views of the RV infundibulum, pulmonary valve, and main/proximal branch pulmonary arteries. The short-axis view also allows for visualization of the coronary ostia, and imaging and color flow mapping of the proximal coronary arteries. Clockwise rotation of the transducer into a transverse view elongates the left coronary artery and often demonstrates its bifurcation. The morphology of the mitral leaflets and valve apparatus is often best seen on a parasternal short-axis view. In larger hearts, color flow mapping of the ventricular septum may require separate short-axis sweeps of the anterior and posterior portions of the septum.

Examination of the apical muscular septum may require repositioning of the transducer toward the apex during the short-axis sweep.

A ductal view is obtained from imaging in a parasagittal plane from a high left parasternal window. This window lines up the ultrasound beam with the main pulmonary artery-ductus continuum and allows for exclusion of a normally located small patent ductus arteriosus. The distal aortic arch and superior thoracic aorta may also be visualized through the heart and the main pulmonary artery, and, in larger individuals, the aortic isthmus is sometimes best seen from this position. Clockwise rotation of the transducer to a high left parasternal transverse plane may better demonstrate the left pulmonary veins in some larger individuals.

Suprasternal notch views. Imaging from the suprasternal notch³⁸⁻⁴⁰ includes positioning of the transducer in the right supraclavicular region and occasionally in the left supraclavicular region. In the coronal, or short-axis, plane (Figure 7), the

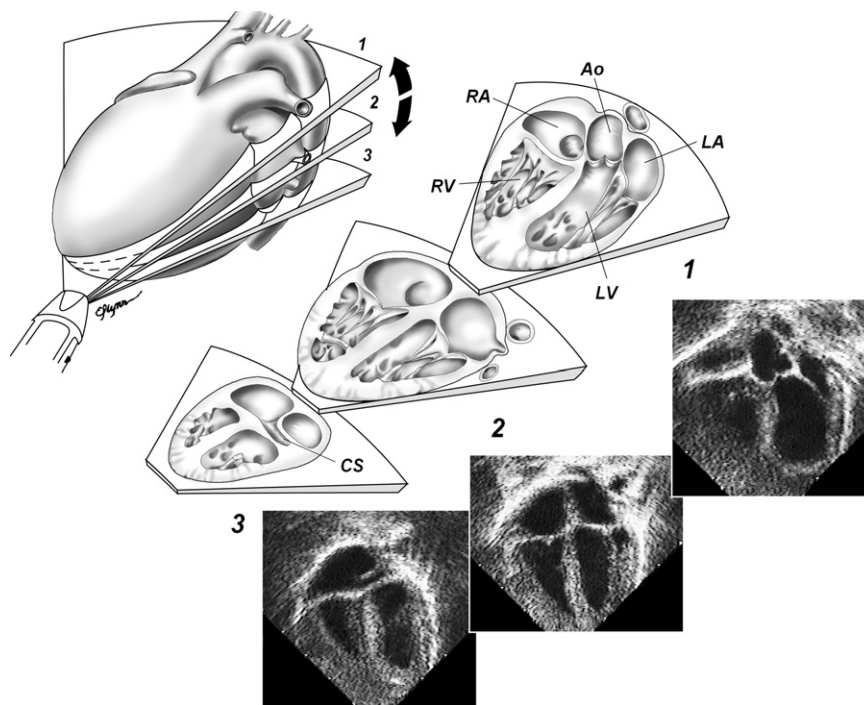


Figure 3 Apical 4-chamber views demonstrated in anterior/superior to posterior/inferior sweep. 1, With anterosuperior angulation, left ventricular (LV) outflow tract and proximal ascending aorta (Ao) are demonstrated. 2, apical 4-chamber view shows atria, atrioventricular valves, and ventricles in cross section. 3, With posterior angulation, coronary sinus (CS) is seen along posterior left atrioventricular groove. (Reproduced with permission from: Geva T. Echocardiography and Doppler ultrasound. In: Garson A, Bricker JT, Fisher DJ, Neish SR, editors. The science and practice of pediatric cardiology. Baltimore: Williams and Wilkins; 1997, p. 789-843).

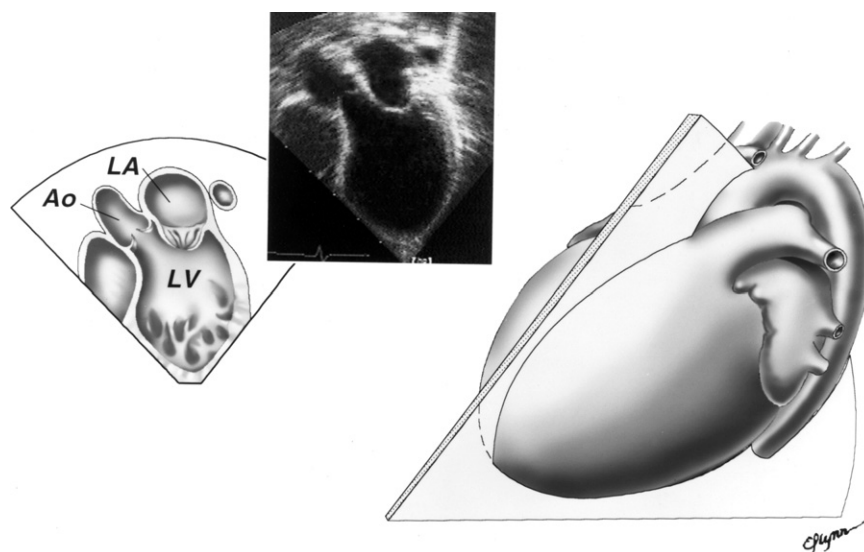


Figure 4 From apical 4-chamber view, clockwise rotation of transducer into apical long-axis view profiles left atrium (LA), left ventricular (LV) outflow tract, and proximal ascending aorta (Ao). (Reproduced with permission from: Geva T. Echocardiography and Doppler ultrasound. In: Garson A, Bricker JT, Fisher DJ, Neish SR, editors. The science and practice of pediatric cardiology. Baltimore: Williams and Wilkins; 1997, p. 789-843).

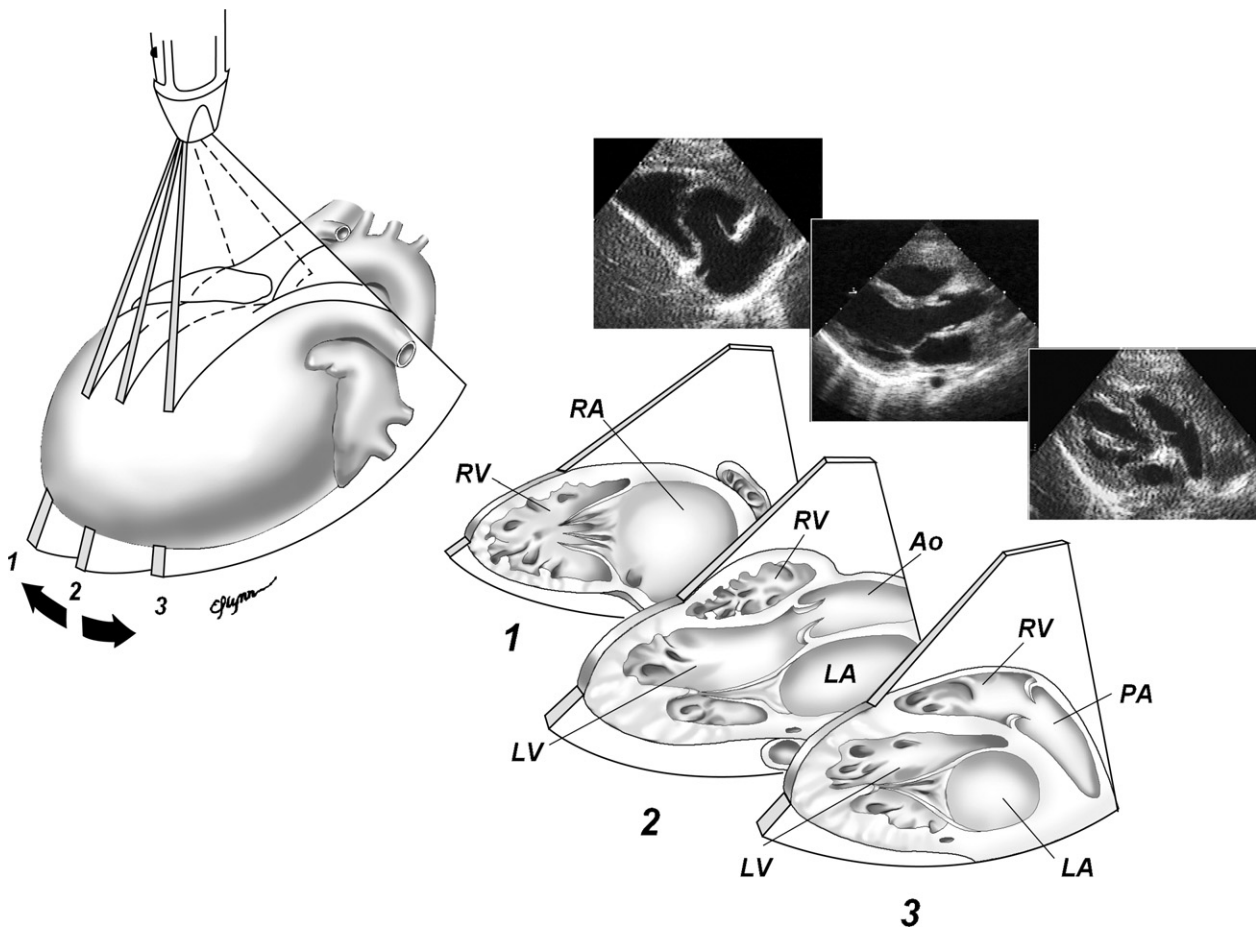


Figure 5 Left parasternal long-axis views demonstrated in rightward/inferior to leftward/superior sweep. 1, Rightward and inferior angulation toward right hip shows right atrium (*RA*), tricuspid valve, and right ventricular (*RV*) inflow. Coronary sinus can be followed into *RA* in this view. 2, Parasternal long-axis view shows left atrium (*LA*), left ventricle (*LV*), mitral and aortic (*Ao*) valves, *RV*, and ascending *Ao*. 3, Leftward and superior angulation toward left shoulder depicts *RV* outflow tract, pulmonary valve, and main pulmonary artery (*PA*). (Reproduced with permission from: Geva T. Echocardiography and Doppler ultrasound. In: Garson A, Bricker JT, Fisher DJ, Neish SR, editors. The science and practice of pediatric cardiology. Baltimore: Williams and Wilkins; 1997, p. 789-843).

connection of the left innominate vein to the superior vena cava is visualized. The leftward extent of the left innominate vein should be examined by color flow mapping to exclude a left superior vena cava or an anomalous pulmonary venous connection. In smaller individuals, both the right and left pulmonary venous connections to the left atrium are well visualized in the far field of the suprasternal notch view (crab view). Superior (cranial) angulation of the transducer demonstrates the branching pattern of the aorta. The sidedness of the aortic arch may be determined as opposite of the direction, or sidedness, of the first brachiocephalic artery. A normal branching pattern of the aortic arch should be documented by demonstration of a normally bifurcating first brachiocephalic artery.

Demonstration of the left aortic arch in its long axis (**Figure 8**) is achieved by counterclockwise rotation of the transducer from the coronal plane in the suprasternal notch window. Further counterclockwise rotation and leftward angulation often best demonstrates the left pulmonary artery.

Right parasternal views. The rightward extent of the atrial septum may be well visualized in a parasagittal imaging plane from the right parasternal border.⁴¹ Superior (**Figure 9**) and inferior right parasternal windows may be sought, and positioning of the patient in a right lateral decubitus position is often helpful. From this view, the atrial septum is oriented perpendicular to the plane of insonation, and less dropout artifact is present. Rotation into a short-axis (transverse) imaging plane from a superior right parasternal window allows visualization and color flow mapping of the right

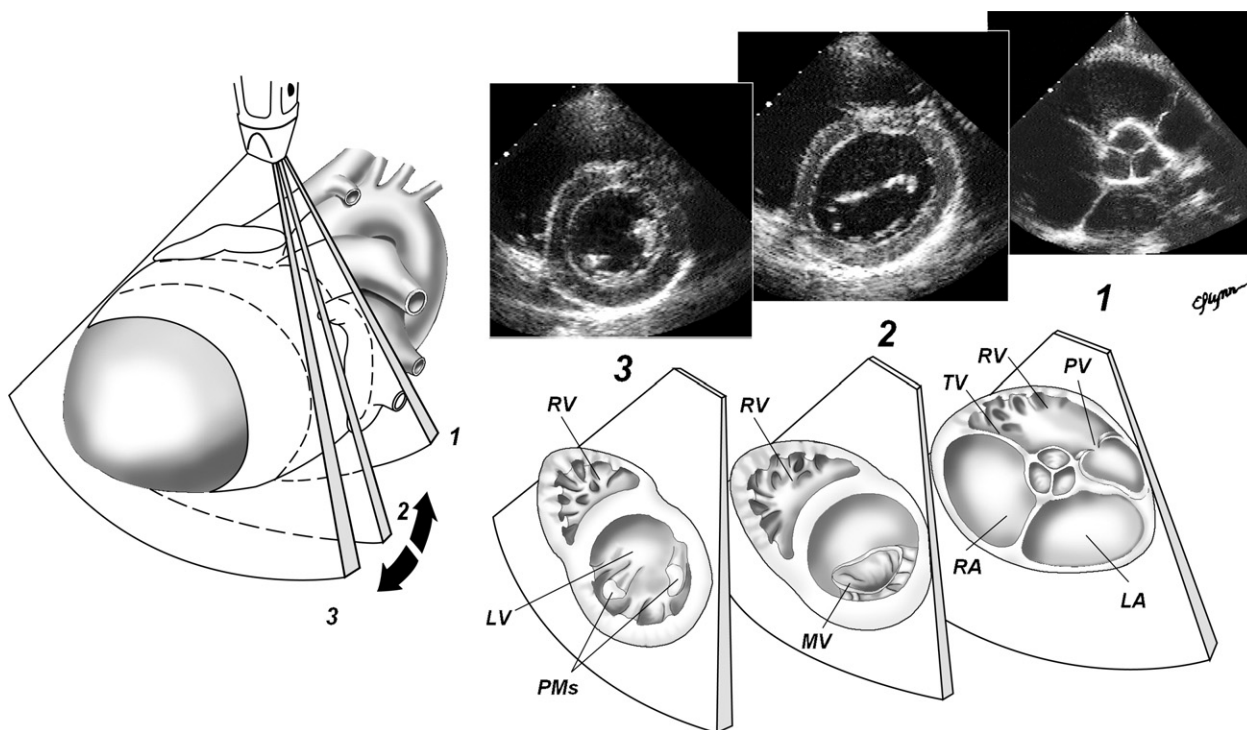


Figure 6 Parasternal short-axis views. 1, Sweep is initiated at base of heart, with right atrium (RA) and left atrium (LA), atrial septum, aortic valve, tricuspid valve (TV), right ventricular (RV) outflow, and pulmonary valve (PV) seen. 2, Cross-sectional view of mitral valve (MV) and RV are then demonstrated. 3, Further angulation toward LV apex depicts LV papillary muscles (PMs) and RV apex. (Reproduced with permission from: Geva T. Echocardiography and Doppler ultrasound. In: Garson A, Bricker JT, Fisher DJ, Neish SR, editors. The science and practice of pediatric cardiology. Baltimore: Williams and Wilkins; 1997, p. 789-843).

upper pulmonary vein and perpendicular interrogation of the right pulmonary artery and its upper lobe branch. Doppler interrogation of the LVOT should also be performed from the right upper parasternal window if indicated.

MEASUREMENTS

The measurement of cardiac structures and flows is critical to the interpretation of a pediatric echocardiogram. An abnormally small or large structure can be a clue to otherwise silent pathology, and is important to the planning of surgical procedures. Mild forms of obstruction can be diagnosed only by accurate measurement of flow velocities. In general, it is recommended that all relevant measurements be made as part of a complete pediatric echocardiogram. Recent guidelines have been published for the echocardiographic assessment of valvar regurgitation⁴² and the quantification of chamber size, ventricular mass, and function in adult patients.⁴³ The measurements that are relevant in pediatric patients, however, will vary depending on the specifics of

their cardiovascular anatomy. The examination protocol of a laboratory should specify which measurements to perform and the laboratory procedure for obtaining each measurement. The following section is a brief discussion of the recommended measurements for a pediatric echocardiogram. The reader is referred to other resources for a more detailed discussion of the theoretic principles for these measurements and for the technical aspects of their performance.⁴³⁻⁵⁰ The recommended measurements are grouped into measurements of cardiovascular structures, ventricular size and function measurements, hemodynamic measurements, and miscellaneous measurements.

Measurements of Cardiovascular Structures

To normalize the measurements of cardiovascular structures, an assessment of body size is necessary. Normative data for many cardiovascular structures exist,⁴⁴⁻⁵⁰ and are generally adjusted to a calculation of body surface area using the height and weight of the patient. Valve and vascular diameters relate linearly to the square root of body surface area, whereas valve and vascular areas relate to body surface area.¹⁸ The

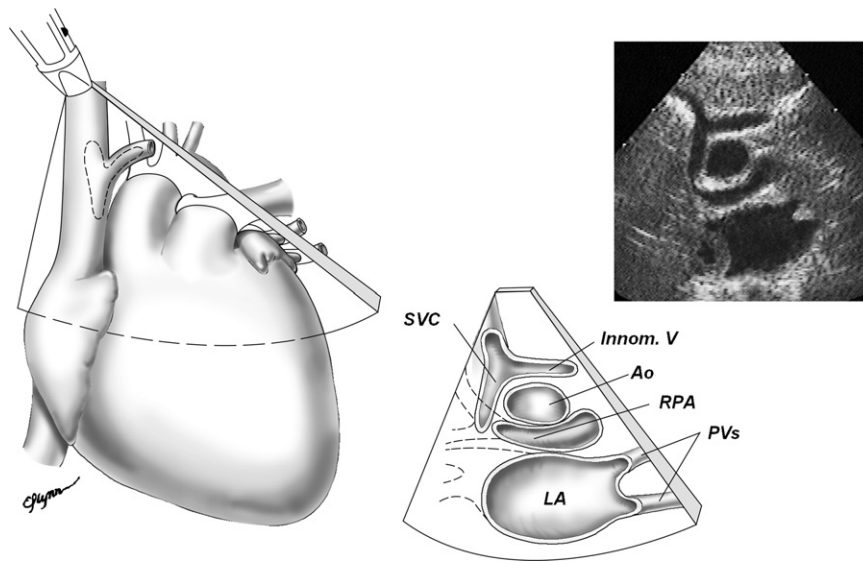


Figure 7 Suprasternal short-axis view. In transverse plane, left innominate vein (*Innom V*) connects with superior vena cava (*SVC*). Distal ascending aorta (*Ao*) is seen in cross section superior to right pulmonary artery (*RPA*), which is seen along its length above left atrium (*LA*). Note pulmonary veins (*PVs*) entering *LA*. (Reproduced with permission from: Geva T. Echocardiography and Doppler ultrasound. In: Garson A, Bricker JT, Fisher DJ, Neish SR, editors. The science and practice of pediatric cardiology. Baltimore: Williams and Wilkins; 1997, p. 789-843).

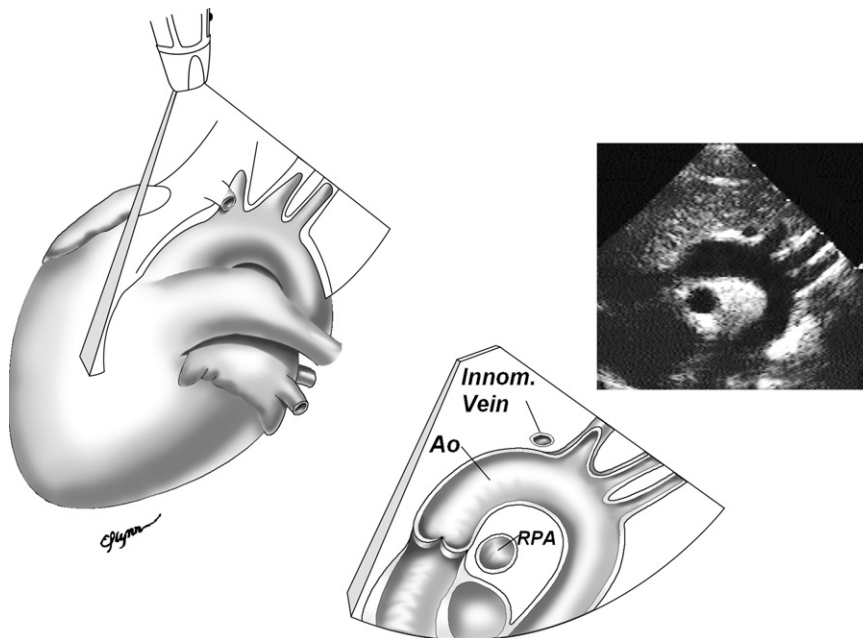


Figure 8 Suprasternal aortic (*Ao*) arch (long-axis) view. Left innominate (*Innom*) vein is seen anterior to *Innom* artery. Right pulmonary artery (*RPA*) is seen in cross section behind ascending *Ao*. (Reproduced with permission from: Geva T. Echocardiography and Doppler ultrasound. In: Garson A, Bricker JT, Fisher DJ, Neish SR, editors. The science and practice of pediatric cardiology. Baltimore: Williams and Wilkins; 1997, p. 789-843).

relationship between LV volume and body size fits a complex model predicted by the nonlinear decrease of heart rate with growth.¹⁸ The 2D measurements have

supplanted those obtained by M-mode as the standard for most cardiac structures. At a minimum, all structures should be imaged adequately so that measure-

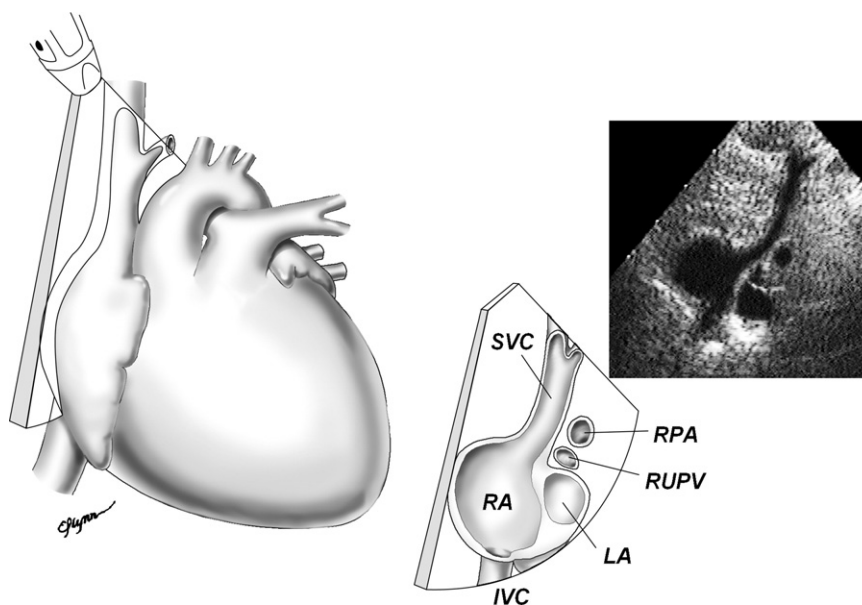


Figure 9 High right parasternal view. Superior vena cava (SVC), right atrium (RA) and left atrium (LA), and atrial septum are demonstrated. Right pulmonary artery (RPA) and right upper pulmonary vein (RUPV) cross behind SVC. (Reproduced with permission from: Geva T. Echocardiography and Doppler ultrasound. In: Garson A, Bricker JT, Fisher DJ, Neish SR, editors. The science and practice of pediatric cardiology. Baltimore: Williams and Wilkins; 1997, p. 789-843).

Table 5 Recommended measurements of cardiovascular structures

Measurement	Timing	View(s)
Tricuspid valve annulus	Diastole	Apical 4-chamber
Pulmonary valve annulus	Systole	PSAX/PLAX
Main pulmonary artery	Systole	PSAX/PLAX
Left/right pulmonary artery	Systole	PSAX/PLAX
Left atrial diameter	Diastole	PLAX
Mitral valve diameter	Diastole	PLAX/apical 4-chamber
Aortic valve annulus	Systole	PLAX
Aortic root	Systole	PLAX
Ascending aorta	Systole	PLAX
Transverse aortic arch	Systole	SSN
Aortic isthmus	Systole	SSN

PLAX, Parasternal long-axis; PSAX, parasternal short-axis; SSN, suprasternal notch.

ments could be performed from the recorded image if required. As a rule, outflow measurements should be obtained during ventricular systole and inflow measures during ventricular diastole. Table 5 provides a list of standard measurements of cardiovascular structures along with the appropriate time of measurement and suggested view.

Ventricular Size and Function Measurements

Assessment of cardiac size and function is an integral part of the evaluation of the cardiac status. Therefore, an objective assessment of cardiac function is

recommended. M-mode, 2D imaging, and Doppler methods can be used to assess ventricular function. Newer modalities such as 3-dimensional echocardiography, Doppler tissue imaging, and strain and strain rate calculations are promising new techniques that are currently under investigation. Each technique for ventricular function assessment has strengths and weaknesses that must be considered and balanced to meet the needs of the individual patient.

LV size and systolic function. Measurement of LV dimensions in diastole and systole by M-mode and/or 2D imaging is recommended for a complete study. The parasternal short axis at the midpapillary level is the preferred site for measurement of LV chamber size and wall thickness, but the subcostal short axis can be used as well. The ventricular septum, LV dimension, and LV posterior wall are used to determine LV size and exclude hypertrophy. LV mass, the estimated weight of the ventricular muscle that can be assessed by several techniques,⁴³ may be helpful in patients with long-standing hypertension or other forms of LV hypertrophy. The standard M-mode method of LV systolic function assessment is the shortening fraction, which is affected by loading conditions, altered LV geometry, and regional wall-motion abnormalities. However, relatively load-independent indices of myocardial performance based on M-mode measurements are useful for the serial assessment of patients at high risk for diminished function, such as those undergoing chemotherapy.

The velocity of circumferential fiber shortening normalized for heart rate is a measure of contractility that is independent of preload and inversely related to afterload in a linear fashion.⁵¹ Two of the more commonly used 2D methods of LV systolic function assessment are the biplane Simpson and the area-length measurements of the ejection fraction. The biplane Simpson method, or the method of disks, calculates a volume based on diastolic and systolic area measurements of the LV from the apical 4- and 2-chamber views. The apical long-axis (3-chamber) view may be substituted for the apical 2-chamber view.^{52,53} The area-length method is calculated using the ventricular length from the apical 4-chamber view and the midpapillary parasternal short-axis area to yield a ventricular volume based on an assumed shape. Both have been validated in children of various sizes.⁵⁴ Calculation of LV wall stress-velocity index has been shown to be a more accurate assessment of the cardiac muscle function and reserve than the ejection fraction, because it incorporates and accounts for the afterload of the ventricle in its evaluation. It may be appropriate for some patients with significant systolic dysfunction or other complicated clinical situations.⁵⁵⁻⁵⁷

RV size and systolic function. Because of its complex geometry, the RV is difficult to accurately assess in short axis, and is often not of benefit in the evaluation of patients. Recommendations for the quantification of the RV and RV OT have been proposed⁴³ but not completely validated in children. Because of the RV's nongeometric shape, no 2D method of shortening or ejection fraction has been consistently applied. The above-mentioned newer modalities (3-dimensional echocardiography, Doppler tissue imaging, and strain and strain rate calculations) are free of geometric assumptions and merit further investigation as techniques for assessing the RV.

Diastolic function. The measurement of ventricular diastolic function is playing an increasingly important role in the evaluation of cardiac dynamics as we learn more about the mechanics of diastole and its impact on overall cardiac status. Ventricular diastolic dysfunction often precedes systolic dysfunction in disease states. Traditional measures have included Doppler indices of LV filling and pulmonary venous flow (Table 6).⁵⁸ The value of additional measurements—including Doppler tissue imaging of the septal and lateral ventricular walls, inflow propagation, isovolumic relaxation time, and Tei index—for assessing diastolic function are being examined.^{59,60}

Hemodynamic Measurements

Measurements of flow through all of the cardiac valves should be part of a complete pediatric echocardiogram. At a minimum, spectral Doppler flow

Table 6 Doppler measurements

Structure	Measurements*
Tricuspid valve	E wave velocity, A wave velocity, deceleration time, IVRT, mean gradient, regurgitant jet velocity
RV outflow	Peak gradient, mean gradient, VTI
Pulmonary valve	Peak gradient, mean gradient, regurgitant jet velocity, VTI
Branch pulmonary artery	Peak gradient, mean gradient, VTI
Mitral valve	E wave velocity, A wave velocity, deceleration time, IVRT, mean gradient
LV outflow	Peak gradient, mean gradient, VTI
Aortic valve	Peak gradient, mean gradient, VTI, pressure half-time
Aortic arch	Peak gradient, mean gradient, VTI

IVRT, Isovolumic relaxation time; LV, left ventricular; RV, right ventricular; VTI, velocity time integral.

*Recording of images adequate for the measurements listed should be considered for inclusion in a complete examination protocol. This is not intended to be a comprehensive list of recommended Doppler measurements.

images should be recorded so that measurements of the gradients across all intracardiac valves and great arteries can be performed. Table 6 lists Doppler measurements that should be considered for inclusion in a complete examination protocol. If evidence of flow obstruction is present, more complete measurement of cardiovascular dimensions (subvalvar, valvar, supra-valvar, vascular, or a combination of these) and flow gradients should be performed. To properly evaluate the intracardiac and intravascular pressures, a representative blood pressure measurement must be obtained. In some patients, repeated measurement may be appropriate if there is changing physiology or if an exact comparison is required at the time of a particular measurement. In patients with congenital heart disease, it is particularly important to estimate RV and pulmonary artery pressures and to note their estimated values relative to systemic pressures.

Miscellaneous and Pathology-related Measurements

There are measurements that may be appropriate for certain patients with specific types of pathology. For example, in patients with Marfan syndrome, the aorta should be measured at multiple levels. Patients with a ventricular septal defect require assessment of defect size and flow velocity as part of their evaluation. Likewise, assessment of descending aortic flow is important in patients with aortic insufficiency or aortopulmonary communications. However, the breadth and variability of these measurements is beyond the scope of these guidelines.

Table 7 Minimal elements for a pediatric echocardiography report

Patient identifier data
Name
Date of birth
Medical record identifier
Date of study
Location of study
Referring physician
Sedation used
Indications for pediatric echocardiographic study
Sonographer/physician who performed the study
Findings section
Structural/anatomic features
Quantitative data
Doppler (hemodynamic) findings
Summary section

REPORTING

Information obtained from pediatric echocardiograms is frequently used by nonechocardiographic personnel, including surgeons, pediatricians, anesthesiologists, and other patient caretakers. Conveyance of the echocardiographic findings in a clear and cogent manner is important. Abbreviations should be avoided but when used should be unambiguous.

Minimal elements of the pediatric echocardiography report are listed in Table 7. Basic identifier information should be listed. A statement relating to the indication for study is required. The report findings section can be configured in a variety of ways but should include information on: (1) structural findings; (2) measurements of cardiovascular structures made; and (3) Doppler echocardiographic data. Positive findings and pertinent negative findings should be listed.

Information pertaining to cardiovascular anatomy and structure can be conveyed using the segmental approach. In addition to reporting the absolute values, it is useful to report quantitative measures within the context of age- or size-appropriate norms (eg, z-score values).^{61,62} Doppler information concerning the atrioventricular valves, semilunar valves, and any shunt sites should be provided. Quantitative Doppler information such as velocity data, patterns of spectral flow, and color jet dimensions, and semiquantitative estimates of insufficiency or stenosis, where appropriate, should be included in the report. Any technical or other limitations that might compromise the diagnostic accuracy of the echocardiographic examination should be specified in the report. Examples include suboptimal acoustic windows, heart rate constraints, and excessive patient motion during the examination.

A standardized pediatric echocardiography report should be generated for every echocardiographic study performed. The final report may be generated electronically with the option of a printable paper copy. The report should be easily accessible to appropriate personnel and readily available for review at all times. Reports should be searchable and available for serial comparison.

NEWER MODALITIES

The recent advent of echocardiographic modalities such as Doppler imaging of tissue velocities, including strain and strain rate imaging, color M-mode assessment of atrioventricular valve inflows, and live 3-dimensional echocardiography portends great promise for the near future.⁶³⁻⁹⁰ The quantitative approaches available from the application of these modalities promise to provide a new paradigm for the echocardiographic assessment of myocardial and valvar function. Other innovative technologies, such as handheld echocardiography scanners, may expand the applicability of pediatric echocardiography.⁹¹⁻⁹³ This document does not seek to establish standards for these newer modalities.

Conclusion

The pediatric echocardiogram is a unique ultrasound examination, which differs in important ways from the conventional echocardiogram in the adult. A standardized approach and specialized skills and knowledge are required to perform and interpret this test appropriately. This statement outlines indications, details the unique features and essential components of the pediatric echocardiogram, and establishes standards for the performance, interpretation, and reporting of this important test.

REFERENCES

1. Henry WL, DeMaria A, Gramiak R, et al. Report of the American Society of Echocardiography committee on nomenclature and standards in two-dimensional echocardiography. *Circulation* 1980;62:212-5.
2. Rychik J, Ayres N, Cunco B, et al. American Society of Echocardiography guidelines and standards for performance of the fetal echocardiogram. *J Am Soc Echocardiogr* 2004;17:803-10.
3. Ayres N, Miller-Hance W, Fyfe DA, et al. Indications and guidelines for performance of transesophageal echocardiography in the patient with acquired or congenital heart disease. *J Am Soc Echocardiogr* 2005;18:91-8.
4. Shanewise J, Cheung A, Aronson S, et al. ASE/SCA guidelines for performing a comprehensive intraoperative multiplane transesophageal echocardiography examination: recommendations of the American Society of Echocardiography council for intraoperative echocardiography and the Society of Cardiovascular Anesthesiologists task force for certification in

- perioperative transesophageal echocardiography. *J Am Soc Echocardiogr* 1999;12:884-900.
5. Armstrong W, Pellikka P, Ryan T, Crouse L, Zoghbi WA. Stress echocardiography: recommendations for performance and interpretation of stress echocardiography. *J Am Soc Echocardiogr* 1998;11:97-104.
 6. Douglas P, Foster E, Gorcsan J III, et al. ACC/AHA clinical competence statement on echocardiography. *J Am Coll Cardiol* 2003;41:687-708.
 7. Meyer R, Hagler D, Huhta J, et al. Guidelines for physician training in fetal echocardiography: recommendations of the Society of Pediatric Echocardiography committee on physician training. *J Am Soc Echocardiogr* 1990;3:1-3.
 8. Meyer R, Hagler D, Huhta J, Smallhorn J, Snider R, Williams R. Guidelines for physician training in pediatric echocardiography: recommendations of the Society of Pediatric Echocardiography committee on physician training. *Am J Cardiol* 1987;60:164-5.
 9. Fouron J, Robertson M, Sandor G. Standards for training in pediatric echocardiography: Canadian Cardiovascular Society. *Can J Cardiol* 1998;14:899-901.
 10. Waggoner A, Ehler D, Adams D, et al. Guidelines for the cardiac sonographer in the performance of contrast echocardiography: recommendations of the American Society of Echocardiography council on cardiac sonography. *J Am Soc Echocardiogr* 2001;14:417-20.
 11. Thys DM, Abel M, Bollen BA, et al. Practice guidelines for perioperative transesophageal echocardiography: a report by the American Society of Anesthesiologists and the Society of Cardiovascular Anesthesiologists task force on transesophageal echocardiography. *Anesthesiology* 1996;84:986-1006.
 12. Stewart W, Douglas P, Sagar K, et al. Echocardiography in emergency medicine: a policy statement by the American Society of Echocardiography and the American College of Cardiology. *J Am Soc Echocardiogr* 1999;12:82-4.
 13. ICAEL online: how to apply the standards for echocardiography laboratories. From the intersocietal commission for the accreditation of echocardiography laboratories. Columbia, MD: 2002. Available from: URL:<http://www.intersocietal.org/icael/apply/standards.htm>. Accessed April 2002.
 14. Cheitlin MD, Alpert JS, Armstrong WF, et al. ACC/AHA guidelines for the clinical application of echocardiography: a report of the American College of Cardiology/American Heart Association task force on practice guidelines (committee on clinical application of echocardiography). *Circulation* 1997;95:1687-744.
 15. Gutgesell HP, Rembold CM. Growth of the human heart relative to body surface area. *Am J Cardiol* 1990;65:662-8.
 16. Geva T, Ayres NA, Pac FA, Pignatelli R. Quantitative morphometric analysis of progressive infundibular obstruction in tetralogy of Fallot: a prospective longitudinal echocardiographic study. *Circulation* 1995;92:886-92.
 17. McElhinney DB, Yang SG, Hogarty AN, et al. Recurrent arch obstruction after repair of isolated coarctation of the aorta in neonates and young infants: is low weight a risk factor? *J Thorac Cardiovasc Surg* 2001;122:883-90.
 18. Shluysmans T, Colan SD. Theoretical and empirical derivation of cardiovascular allometric relationships in children. *J Appl Physiol* 2005;99:445-57.
 19. Falkner B, Daniels SR. Summary of the fourth report on the diagnosis, evaluation and treatment of high blood pressure in children and adolescent. *Hypertension* 2004;44:387-8.
 20. American Academy of Pediatrics: Committee on Drugs. Guidelines for monitoring and management of pediatric patients during and after sedation for diagnosis and therapeutic procedures. *Pediatrics* 1992;89:1110-5.
 21. American Academy of Pediatrics: Committee on Drugs. Guidelines for monitoring and management of pediatric patients during and after sedation for diagnosis and therapeutic procedures: addendum. *Pediatrics* 2002;110:836-8.
 22. Mertens L, Helbing W, Sieverding L, Daniela O, on behalf of the Working Group on Cardiac Imaging of the Association for European Paediatric Cardiology. Standards for training in paediatric echocardiography. *Cardiol Young* 2005;15:441-2.
 23. Cheitlin MD, Armstrong WF, Aurigemma GP, et al. ACC/AHA/ASE 2003 guideline update for the clinical application of echocardiography: summary article; a report of the ACC/AHA task force on practice guidelines (ACC/AHA/ASE committee to update the 1997 guidelines for the clinical application of echocardiography). *J Am Soc Echocardiogr* 2003;16:1091-110.
 24. Quinones MA, Douglas PS, Foster E, et al. ACC/AHA clinical competence statement on echocardiography: a report of the ACC/AHA/ACP-ASIM task force on clinical competence. *J Am Soc Echocardiogr* 2003;16:379-402.
 25. Sanders SP, Colan SD, Cordes TM, et al. ACC/AHA/AAP recommendations for training in pediatric cardiology Task force 2: pediatric training guidelines for noninvasive cardiac imaging endorsed by the American Society of Echocardiology and the Society of Pediatric Echocardiography. *J Am Coll Cardiol* 2005;46:1384-8.
 26. Bierig SM, Ehler D, Knoll ML, Waggoner AD. ASE minimum standards for the cardiac sonographer: a position paper. *J Am Soc Echocardiogr* 2006;19:471-4.
 27. Thomas JD, Adams DB, DeVries S, et al. Guidelines and recommendations for digital echocardiography. *J Am Soc Echocardiogr* 2005;18:287-97.
 28. Frommelt PC, Whitstone EN, Frommelt MA. Experience with a DICOM-compatible digital pediatric echocardiography laboratory. *Pediatr Cardiol* 2002;23:53-7.
 29. Mathewson JW, Dyar D, Jones FD, Sklansky MS, Perry JC, Michelfelder EC, et al. Conversion to digital technology improves efficiency in the pediatric echocardiography laboratory. *J Am Soc Echocardiogr* 2002;15:1515-22.
 30. Van Praagh R. Diagnosis of complex congenital heart disease: morphologic-anatomic method and terminology. *Cardiovasc Intervent Radiol* 1984;7:115-20.
 31. Anderson RH, Becker AE, Freedom RM, et al. Sequential segmental analysis of congenital heart disease. *Pediatr Cardiol* 1984;5:281-7.
 32. Henry WL, DeMaria A, Gramiak R, et al. Report of the American Society of Echocardiography committee on nomenclature and standards in two-dimensional echocardiography. *Circulation* 1980;62:212-7.
 33. Bierman FZ, Williams RG. Subxiphoid two-dimensional imaging of the interatrial septum in infants and neonates with congenital heart disease. *Circulation* 1979;60:80-90.
 34. Lange LW, Sahn DJ, Allen HD, Goldberg SJ. Subxiphoid cross-sectional echocardiography in infants and children with congenital heart disease. *Circulation* 1979;59:513-24.
 35. Silverman NH, Schiller NB. Apex echocardiography: a two-dimensional technique for evaluation of congenital heart disease. *Circulation* 1978;57:502-11.
 36. Tanaka M, Neyazaki T, Kosaka S, et al. Ultrasonic evaluation of anatomical abnormalities of heart in congenital and acquired heart diseases. *Br Heart J* 1971;33:686-98.
 37. Tajik AJ, Seward JB, Hagler DJ, Mair DD, Lie JT. Two-dimensional real-time ultrasonic imaging of the heart and

- great vessels: technique, image orientation, structure identification and validation. *Mayo Clin Proc* 1978;53:271-303.
38. Allen HD, Goldberg SJ, Sahn DJ, Ovitt TW, Goldberg BB. Suprasternal notch echocardiography: assessment of its clinical utility in pediatric cardiology. *Circulation* 1977;55:605-12.
 39. Sahn DJ, Allen HD, McDonald G, Goldberg SJ. Real-time cross-sectional echocardiographic diagnosis of coarctation of the aorta: a prospective study of echocardiographic-angiographic correlations. *Circulation* 1977;56:762-9.
 40. Snider AR, Silverman NH. Suprasternal notch echocardiography: a two-dimensional technique for evaluating congenital heart disease. *Circulation* 1981;63:165-73.
 41. McDonald RW, Rice MJ, Reller MD, Marcella CP, Sahn DJ. Echocardiographic imaging techniques with subcostal and right parasternal longitudinal views in detecting sinus venosus atrial septal defects. *J Am Soc Echocardiogr* 1996;9:195-8.
 42. Zoghbi WA, Enriquez-Sarano M, Foster E, Grayburn PA, Kraft CD, Levine RA, et al; American Society of Echocardiography. Recommendations for evaluation of the severity of native valvular regurgitation with two-dimensional and Doppler echocardiography. *J Am Soc Echocardiogr* 2003;16:777-802.
 43. Lang RM, Bierig M, Devereux RB, et al. Recommendations for chamber quantification: a report from the American Society of Echocardiography's guidelines and standards committee and the chamber quantification writing group. *J Am Soc Echocardiogr* 2005;18:1440-63.
 44. Akiba T, Yoshikawa M, Otaki S, et al. Echocardiographic measurements of left ventricle in normal infants and children. *Tohoku J Exp Med* 1986;149:31-7.
 45. Daubeney PEF, Blackstone EH, Weintraub RG, et al. Relationship of the dimension of cardiac structures to body size: an echocardiographic study in normal infants and children. *Cardiol Young* 1999;9:402-10.
 46. King DH, Smith EO, Huhta JC, Gutgesell HP. Mitral and tricuspid valve annular diameter in normal children determined by two-dimensional echocardiography. *Am J Cardiol* 1985;55:787-9.
 47. Nidorf SM, Picard MH, Triulzi MO, et al. New perspectives in the assessment of cardiac chamber dimensions during development and adulthood. *J Am Coll Cardiol* 1992;19:983-8.
 48. Snider AR, Enderlein MA, Teitel DF, Juster RP. Two-dimensional echocardiographic determination of aortic and pulmonary artery sizes from infancy to adulthood in normal subjects. *Am J Cardiol* 1984;53:218-24.
 49. Sahn DJ, DeMaria A, Kisslo J, Weyman A. Recommendations regarding quantitation in M-mode echocardiography: results of a survey of echocardiographic measurements. *Circulation* 1978;58:1072-83.
 50. Methods for obtaining quantitative information from the echocardiographic examination. In: Snider AR, Serwer GA, Ritter SB, editors. *Echocardiography in pediatric heart disease*. 2nd ed. St Louis: Mosby; 1997. p. 133-234.
 51. Colan SD, Borow KM, Neumann A. Left ventricular end-systolic wall stress-velocity of fiber shortening relation: a load-independent index of myocardial contractility. *J Am Coll Cardiol* 1984;4:715-24.
 52. Nosir YF, Vletter WB, Boersma E, et al. The apical long-axis rather than the two-chamber view should be used in combination with the four-chamber view for accurate assessment of left ventricular volumes and function. *Eur Heart J* 1997;18:1175-85.
 53. Malm S, Sagberg E, Larsson H, Skjaerpe T. Choosing apical long-axis instead of two-chamber view gives more accurate biplane echocardiographic measurements of left ventricular ejection fraction: a comparison with magnetic resonance imaging. *J Am Soc Echocardiogr* 2005;18:1044-50.
 54. Silverman NH, Schiller NB. Cross sectional echocardiographic assessment of cardiac chamber size and ejection fraction in children. *Ultrasound Med Biol* 1984;10:757-69.
 55. Colan SD, Sanders SP, Ingelfinger JR, Harmon W. Left ventricular mechanics and contractile state in children and young adults with end-stage renal disease: effect of dialysis and renal transplantation. *J Am Coll Cardiol* 1987;10:1085-94.
 56. Borow KM, Colan SD, Neumann A. Altered left ventricular mechanics in patients with valvular aortic stenosis and coarctation of the aorta: effects on systolic performance and late outcome. *Circulation* 1985;72:515-22.
 57. Lipshultz SE, Colan SD, Gelber RD, Perez-Atayde AR, Sallan SE, Sanders SP. Late cardiac effects of doxorubicin therapy for acute lymphoblastic leukemia in childhood. *N Engl J Med* 1991;324:808-15.
 58. Appleton CP, Jensen JL, Hatle LK, Oh JK. Doppler evaluation of left and right ventricular diastolic function: a technical guide for obtaining optimal flow velocity recordings. *J Am Soc Echocardiogr* 1997;10:271-92.
 59. Khouri SJ, Maly GT, Suh DD, Walsh TE. A practical approach to the echocardiographic evaluation of diastolic function. *J Am Soc Echocardiogr* 2004;17:290-7.
 60. Zhang H, Otsuji Y, Matsukida K, et al. Noninvasive differentiation of normal from pseudonormal/restrictive mitral flow using Tei index combining systolic and diastolic function. *Circ J* 2002;66:831-6.
 61. Fisher SD, Easley KA, Orav EJ, Colan SD, Kaplan S, Starc TJ, et al. Mild dilated cardiomyopathy and increased left ventricular mass predict mortality: the prospective P²C² HIV multicenter study. *Am Heart J* 2005;150:439-47.
 62. Daubeney PE, Blackstone EH, Weintraub RG, Slavik Z, Scanlon J, Webber SA. Relationship of the dimension of cardiac structures to body size: an echocardiographic study in normal infants and children. *Cardiol Young* 1999;9:402-10.
 63. Koliaas TJ, Aaronson KD, Armstrong WF. Doppler-derived dP/dt and -dP/dt predict survival in congestive heart failure. *J Am Coll Cardiol* 2000;36:1594-9.
 64. Michelfelder EC, Vermilion RP, Ludomirsky A, Beekman RH, Lloyd TR. Comparison of simultaneous Doppler- and catheter-derived right ventricular dP/dt in hypoplastic left heart syndrome. *Am J Cardiol* 1996;77:212-4.
 65. Bruch C, Gotzmann M, Stypmann J, et al. Electrocardiography and Doppler echocardiography for risk stratification in patients with chronic heart failure: incremental prognostic value of QRS duration and a restrictive mitral filling pattern. *J Am Coll Cardiol* 2005;45:1072-5.
 66. Schwammenthal E, Popescu BA, Popescu AC, et al. Association of left ventricular filling parameters assessed by pulsed wave Doppler and color M-mode Doppler echocardiography with left ventricular pathology, pulmonary congestion, and left ventricular end-diastolic pressure. *Am J Cardiol* 2004;94:488-91.
 67. Dokainish H, Zoghbi WA, Lakkis NM, et al. Incremental predictive power of B-type natriuretic peptide and tissue Doppler echocardiography in the prognosis of patients with congestive heart failure. *J Am Coll Cardiol* 2005;45:1223-6.
 68. Gomez CA, Ludomirsky A, Ensing GJ, Rocchini AP. Effect of acute changes in load on left ventricular diastolic function

- during device closure of atrial septal defects. *Am J Cardiol* 2005;95:686-8.
69. McMahon CJ, Nagueh SF, Eapen RS, et al. Echocardiographic predictors of adverse clinical events in children with dilated cardiomyopathy: a prospective clinical study. *Heart* 2004;90:908-15.
 70. McMahon CJ, Nagueh SF, Pignatelli RH, et al. Characterization of left ventricular diastolic function by tissue Doppler imaging and clinical status in children with hypertrophic cardiomyopathy. *Circulation* 2004;109:1756-62.
 71. Dini FL, Michelassi C, Micheli G, Rovai D. Prognostic value of pulmonary venous flow Doppler signal in left ventricular dysfunction: contribution of the difference in duration of pulmonary venous and mitral flow at atrial contraction. *J Am Coll Cardiol* 2000;36:1295-302.
 72. Troughton RW, Prior DL, Pereira JJ, et al. Plasma B-type natriuretic peptide levels in systolic heart failure: importance of left ventricular diastolic function and right ventricular systolic function. *J Am Coll Cardiol* 2004;43:416-22.
 73. Wang M, Yip GW, Wang AY, et al. Peak early diastolic mitral annulus velocity by tissue Doppler imaging adds independent and incremental prognostic value. *J Am Coll Cardiol* 2003;41:820-6.
 74. Harada K, Tamura M, Toyono M, Yasuoka K. Comparison of the right ventricular Tei index by tissue Doppler imaging to that obtained by pulsed Doppler in children without heart disease. *Am J Cardiol* 2002;90:566-9.
 75. Nishimura R, Tajik A. Evaluation of diastolic filling of left ventricle in health and disease: Doppler echocardiography is the clinician's Rosetta stone. *J Am Coll Cardiol* 1997;30:8-18.
 76. Larrazet F, Bouabdallah K, Le Bret E, Vouhe P, Veyrat C, Laborde F. Tissue Doppler echocardiographic and color M-mode estimation of left atrial pressure in infants. *Pediatr Crit Care Med* 2005;6:448-53.
 77. Mertens L. Noninvasive assessment of filling pressures in the pediatric intensive care unit: is it possible? *Pediatr Crit Care Med* 2005;6:496-7.
 78. Gutierrez-Chico JL, Zamorano JL, Perez de Isla L, et al. Comparison of left ventricular volumes and ejection fractions measured by three-dimensional echocardiography versus by two-dimensional echocardiography and cardiac magnetic resonance in patients with various cardiomyopathies. *Am J Cardiol* 2005;95:809-13.
 79. Bu L, Munns S, Zhang H, et al. Rapid full volume data acquisition by real-time 3-dimensional echocardiography for assessment of left ventricular indexes in children: a validation study compared with magnetic resonance imaging. *J Am Soc Echocardiogr* 2005;18:299-305.
 80. Jenkins C, Bricknell K, Hanekom L, Marwick TH. Reproducibility and accuracy of echocardiographic measurements of left ventricular parameters using real-time three-dimensional echocardiography. *J Am Coll Cardiol* 2004;44:878-86.
 81. Zeidan Z, Erbel R, Barkhausen J, Hunold P, Bartel T, Buck T. Analysis of global systolic and diastolic left ventricular performance using volume-time curves by real-time three-dimensional echocardiography. *J Am Soc Echocardiogr* 2003;16:29-37.
 82. Kuhl HP, Schreckenber M, Rulands D, et al. High-resolution transthoracic real-time three-dimensional echocardiography: quantitation of cardiac volumes and function using semi-automatic border detection and comparison with cardiac magnetic resonance imaging. *J Am Coll Cardiol* 2004;43:2083-90.
 83. Fei HW, Wang XF, Xie MX, et al. Validation of real-time three-dimensional echocardiography for quantifying left and right ventricular volumes: an experimental study. *Chin Med J (Engl)* 2004;117:695-9.
 84. Sheehan FH, Bolson JA, McDonald JA. Applications of three-dimensional echocardiography beyond the left ventricle: other chambers and structural detail. *Comput Cardiol* 2000;27:119-222.
 85. Lange A, Palka P, Donnelly J, Burstow D. Quantification of mitral regurgitation orifice area by 3-dimensional echocardiography: comparison with effective regurgitant orifice area by PISA method and proximal regurgitant jet diameter. *Int J Cardiol* 2002;86:87-98.
 86. Heusch A, Rubo J, Krogmann ON, Bourgeois M. Volumetric analysis of the right ventricle in children with congenital heart defects: comparison of biplane angiography and transthoracic 3-dimensional echocardiography. *Cardiol Young* 1999;9:577-84.
 87. Hubka M, Mantei K, Bolson E, Coady K, Sheehan F. Measurement of right ventricular mass and volume by three-dimensional echocardiography by freehand scanning. *Comput Cardiol* 2000;27:703-6.
 88. Sitges M, Jones M, Shiota T, et al. Real-time three-dimensional color Doppler evaluation of the flow convergence zone for quantification of mitral regurgitation: validation experimental animal study and initial clinical experience. *J Am Soc Echocardiogr* 2003;16:38-45.
 89. Pemberton J, Li X, Karamlou T, et al. The use of live three-dimensional Doppler echocardiography in the measurement of cardiac output: an in vivo animal study. *J Am Coll Cardiol* 2005;45:433-8.
 90. Li X, Ashraf M, Thiele K, et al. A novel method for the assessment of the accuracy of computing laminar flow stroke volumes using a real-time 3D ultrasound system: in vitro studies. *Eur J Echocardiogr* 2005;6:396-404.
 91. Scholten C, Rosenhek R, Binder T, Zehetgruber M, Maurer G, Baumgartner H. Hand-held miniaturized cardiac ultrasound instruments for rapid and effective bedside diagnosis and patient screening. *J Eval Clin Pract* 2005;11:67-72.
 92. Gorcsan J. Utility of hand-carried ultrasound for consultative cardiology. *Echocardiography* 2003;20:463-9.
 93. Xie T, Chamoun AJ, McCulloch M, Tsiouris N, Birnbaum Y, Ahmad M. Rapid screening of cardiac patients with a miniaturized hand-held ultrasound imager-comparisons with physical examination and conventional two-dimensional echocardiography. *Clin Cardiol* 2004;27:241-5.