

Children's Mercy Kansas City

SHARE @ Children's Mercy

Manuscripts, Articles, Book Chapters and Other Papers

12-1-2018

Pediatric Nasogastric Tube Placement and Verification: Best Practice Recommendations From the NOVEL Project.

Sharon Y. Irving

Gina Rempel

Beth Lyman

Children's Mercy Hospital

Wednesday Marie A Sevilla

LaDonna Northington

See next page for additional authors

Let us know how access to this publication benefits you

Follow this and additional works at: <https://scholarlyexchange.childrensmercy.org/papers>



Part of the [Dietetics and Clinical Nutrition Commons](#), and the [Equipment and Supplies Commons](#)

Recommended Citation

Irving SY, Rempel G, Lyman B, et al. Pediatric Nasogastric Tube Placement and Verification: Best Practice Recommendations From the NOVEL Project. *Nutr Clin Pract.* 2018;33(6):921-927. doi:10.1002/ncp.10189

This Article is brought to you for free and open access by SHARE @ Children's Mercy. It has been accepted for inclusion in Manuscripts, Articles, Book Chapters and Other Papers by an authorized administrator of SHARE @ Children's Mercy. For more information, please contact hlsteel@cmh.edu.

Creator(s)

Sharon Y. Irving, Gina Rempel, Beth Lyman, Wednesday Marie A Sevilla, LaDonna Northington, Peggi Guenter, and American Society for Parenteral and Enteral Nutrition

Pediatric Nasogastric Tube Placement and Verification: Best Practice Recommendations From the NOVEL Project

Nutrition in Clinical Practice
Volume 33 Number 6
December 2018 921–927
© 2018 American Society for
Parenteral and Enteral Nutrition
DOI: 10.1002/ncp.10189
wileyonlinelibrary.com

WILEY

**Sharon Y. Irving, PhD, CRNP, FCCM, FAAN^{1,2}; Gina Rempel, MD, FRCPC^{3,4};
Beth Lyman, RN, MSN, CNSC, FASPEN⁵; Wednesday Marie A. Sevilla, MD, MPH,
CNSC⁶; LaDonna Northington, DNS, RN, BC⁷; Peggi Guenter, PhD, RN, FAAN,
FASPEN⁸; and The American Society for Parenteral and Enteral Nutrition**

Abstract

The placement of a nasogastric tube (NGT) in a pediatric patient is a common practice that is generally perceived as a benign bedside procedure. There is potential risk for NGT misplacement with each insertion. A misplaced NGT compromises patient safety, increasing the risk for serious and even fatal complications. There is no standardized method for verification of the initial NGT placement or reverification assessment of NGT location prior to use. Measurement of the acidity or pH of the gastric aspirate is the most frequently used evidence-based method to verify NGT placement. The radiograph, when properly obtained and interpreted, is considered the gold standard to verify NGT location. However, the uncertainty regarding cumulative radiation exposure related to radiographs in pediatric patients is a concern. To minimize risk and improve patient safety, there is a need to identify best practice and to standardize care for initial and ongoing NGT location verification. This article provides consensus recommendations for best practice related to NGT location verification in pediatric patients. These consensus recommendations are not intended as absolute policy statements; instead, they are intended to supplement but not replace professional training and judgment. These consensus recommendations have been approved by the American Society for Parenteral and Enteral Nutrition (ASPEN) Board of Directors. (*Nutr Clin Pract.* 2018;33:921–927)

Keywords

enteral nutrition; misplacement; NG feeding tube; pediatric

Introduction

In 2014, a report on 255,140 hospital discharges in the United States revealed that 25% of all patients receiving enteral nutrition (EN) were children. Of those, 6% of the total number of patients were under 12 months of age.¹ This report indicates that a significant number of hospitalized children require feeding tube placement for the administration of EN. A 2016 study reported that approximately 25% of hospitalized pediatric patients require a temporary feeding tube.² The most common enteral feeding tube used in hospitalized children is a nasogastric tube (NGT).² Insertion of an NGT is a high-volume practice commonly performed by nurses as a blind procedure, without the use of technology to guide or visualize the internal path of the tube. Although the vast majority of blind NGT insertions result in successful placement in the intended location—the stomach—each tube can potentially be misplaced, even when the procedure is performed by a healthcare provider experienced in NGT placement. A misplaced NGT compromises patient safety, increasing the risk for severe and even fatal complications.^{3–6} Clinicians practicing in the United States lack guidance for best practice to verify NGT location

when initially placed or for reverification of NGT location before use in pediatric patients. There is a need to identify best practice and standardize care for initial and ongoing verification of NGT location to decrease the risk of a misplaced NGT. Therefore, the objective of this article is to

From the ¹University of Pennsylvania School of Nursing, Philadelphia, Pennsylvania, USA; ²Department of Critical Care Nursing, The Children's Hospital of Philadelphia, Philadelphia, Pennsylvania, USA; ³Rady Faculty of Health Sciences, Max Rady College of Medicine, University of Manitoba, Winnipeg, Canada; ⁴Children's Hospital Winnipeg, Winnipeg, Manitoba, Canada; ⁵Nutrition Support Team, Children's Mercy Hospital, Kansas City, Missouri, USA; ⁶Division of Pediatric Gastroenterology, Children's Hospital of Pittsburgh, University of Pittsburgh Medical Center, Pittsburgh, Pennsylvania, USA; ⁷University of Mississippi Medical Center School of Nursing, Jackson, Mississippi, USA; and ⁸Clinical Practice, Quality, and Advocacy, American Society for Parenteral and Enteral Nutrition (ASPEN), Silver Spring, Maryland, USA.

This article originally appeared online on September 6, 2018.

Corresponding Author:

Sharon Y. Irving, PhD, CRNP, FCCM, FAAN, Assistant Professor, University of Pennsylvania School of Nursing, Claire M. Fagin Hall, 418 Curie Blvd., RM 427, Philadelphia, PA 19104.
Email: ysha@nursing.upenn.edu

develop and disseminate recommendations for best practice related to NGT location verification in pediatric patients based on the available literature.

The consensus recommendations presented here are not intended as absolute policy statements. Use of these practice recommendations does not in any way guarantee any specific benefit in outcome or survival. The professional judgment of the attending health professional is the primary component of quality medical care delivery. Because consensus recommendations cannot account for every variation in circumstances, practitioners must always exercise professional judgment when applying these recommendations to individual patients. These consensus recommendations are intended to supplement, but not replace, professional training and judgment.

Background

The literature is replete with case reports in both pediatric and adult patients describing NGT misplacements.⁵ An early account of submucosal placement of an NGT that occurred in an adult patient under anesthesia was reported by Daly in 1953 and again by Lind et al. in 1978.^{7,8} Complications in adult patients related to NGT placement can be found from the 1970s through the present day.⁸⁻¹¹ Similar reports of misplaced NGTs in children describe insertions into the esophagus,^{4,12,13} pylorus,⁴ pharyngeal mucosa,^{14,15} intracranium,¹⁶ and most commonly the respiratory tract.¹⁷ Both gastric and bladder perforation related to NGT misplacement have been described in children.^{18,19} These reports of misplaced NGTs in both adult and pediatric patients demonstrate the risks associated with insertion, emphasizing that NGT placement is not always a benign procedure, as is often perceived.

Although NGT misplacements have frequently been described in the United States, it is difficult to quantify an actual number of misplacements, particularly in children. There are limitations to state reporting mechanisms, a lack of a national reporting system, and a presumed hesitancy among institutions to provide public access to such information. Without a denominator for the number of NGTs placed and a definitive number of misplacements, it is virtually impossible to accurately quantify the number of NGT misplacements that occur. Pennsylvania is one of few states where reporting of NGT misplacements is required. A 2017 Pennsylvania Patient Safety Authority report describes 166 enteral tube misplacements documented from 2011–2016.²⁰ In this report, 10.2% of the misplacements occurred in pediatric patients, with many of these misplacements associated with adverse events.²⁰ This report is one of few references that quantifies the number of enteral tube misplacements in a defined time period, thus depicting the scope of the problem for verification of NGT location. Despite the lack of robust prevalence data describing NGT

misplacements in pediatric patients in the United States, it is well recognized that even 1 undetected, misplaced NGT may have major implications for the individual patient, the family, and the entire healthcare system.²¹

Although the reporting of NGT misplacements is inconsistent in the United States, the National Health Service (NHS) in the United Kingdom has issued a series of Patient Safety Alert (PSA) reports, the most recent in 2016.²² In that 2016 PSA report spanning 5 years (2011–2016), there were 95 occurrences of NGT misplacement, with 32 deaths from the over 3 million NGT (or orogastric tube) placements recorded.²² The most common error cited was the inaccurate interpretation of a radiograph used to verify NGT position. Other errors cited include the use of unapproved methods for NGT placement verification, nursing error in performing pH testing, and communication failures for which the NGT location was not checked before use. Failure at the organizational level to implement previously identified processes to ensure correct NGT placement was determined to be a primary cause of the misplacements. Thus, a mandate was issued by the NHS to declare NGT misplacement a *never event*, and a PSA was directed to organizations emphasizing the seriousness with which NGT placement is to be regarded, holding both the provider and the organization accountable for patient safety related to NGT location verification.^{22,23}

Current Practice

Correct NGT placement begins with accurate measurement of the length of the tube to be inserted into the patient to reach the stomach. Two methods commonly used by nurses to determine NGT depth are the Nose→Earlobe→Xiphoid process→Midline of the Umbilicus (NEMU) method and the Nose→Earlobe→Xiphoid (NEX) method of measurement. When the 2 methods were evaluated, the NEMU method demonstrated superior accuracy (97% vs 59%) over the NEX method for placement in the stomach.²⁴ Upon closer evaluation, use of the NEX method often resulted in high esophageal NGT misplacement, increasing the risk of aspiration and jeopardizing patient safety.^{24,25}

Current practice to verify NGT location is variable among institutions, patient care units, and providers.^{2,11,26} Commonly used methods for NGT location verification include: auscultation, aspiration with visual inspection of gastric fluids, pH testing of gastric secretions, and radiography.²⁷ Safety and practice alerts warn against the use of auscultation²⁸ and visual inspection of gastric aspirate²⁹ as the means of NGT location verification because neither method is confirmatory, and either can give false affirmation of correct NGT placement. Despite these warnings and practice alerts, recent studies found that these methods are still widely used by nurses caring for both pediatric and adult patients.^{2,30}

Use of Radiographs to Verify NGT Placement

The current gold standard to verify NGT placement is a properly obtained and interpreted radiograph. However, uncertainty regarding cumulative radiation exposure related to radiograph frequency,³¹ as well as concerns over the accurate and consistent interpretation and reporting of NGT location by both radiologists^{32,33} and nonradiologists,³⁴ raise questions regarding the use of radiography for NGT location verification as the gold standard in pediatric patients. Accurate NGT location by radiographic verification depends on clearness of the image, interpretation, and the accuracy and clarity of the radiographic report. The report should contain information on the path of the NGT and the exact location of the tube tip that indicates its readiness for use.³² Concerns of radiation exposure, the variability of technique, and the lack of standardization for the amount of radiation used has led many institutions to use the *as low as reasonably achievable*³⁵ concept for pediatric imaging. Given these factors, radiograph is often not the first-line method used to verify NGT placement in many children's hospitals.² However, it is the standard by which all other methods of verification are compared for accuracy in establishing NGT location.

Use of Gastric pH to Verify NGT Placement

Measurement of the acidity of the gastric aspirate is an evidence-based method used to verify NGT placement. Commercial products to measure pH from gastric aspirate show variance in measurement increments of 0.5–1.0. Studies have demonstrated that obtaining a pH ≤ 5.5 from gastric aspirate obtained from an NGT is a reliable indicator that the tube is properly placed in the stomach.^{4,23,29,36-38} Standard practice in the United Kingdom is to obtain a gastric pH measurement as the primary method to determine NGT location; a pH value of 1–5.5 is considered indicative of correct gastric placement for an NGT.²²

An issue to consider when using gastric aspirate pH measurement to determine NGT location is the use of histamine-2 receptor antagonists (H₂RAs) and/or proton pump inhibitors (PPIs). These classes of medications lower gastric acidity and can result in a pH measurement > 5.5 , causing concern about tube misplacement.⁴ However, a discrepancy of accurate gastric aspirate pH measurements when these medications are used has not been validated in the literature. A recently completed retrospective study of neonates demonstrated that 97% of 6979 pH measurements obtained in 1024 infants were ≤ 5 .³⁹ Whereas not many of the infants received a PPI or H₂RA, 95% and 92% of those who did had pH ≤ 5 , respectively. Additionally, a 2016 retrospective study from a large medical record database reports a significant increase in H₂RA and PPI prescriptions in children over a 6-year (2005–2011) period, with children

less than 12 months of age having the highest prescription rate for H₂RA medications.⁴⁰

A true gastric aspirate is necessary to obtain an accurate pH measurement; therefore, a second issue to consider concerns reverification of correct NGT location in those patients receiving continuous enteral feeding. These patients may require a period of cessation of formula infusion and water or air flush of the NGT to ensure accuracy when obtaining a gastric aspirate to measure pH, although there are no data available to support or refute this practice. A limitation to using gastric pH to assess NGT location arises if the tube is misplaced into the esophagus, where it is difficult to withdraw secretions. More importantly, if esophageal placement occurs, the pH of any aspirate may mimic that of gastric secretions due to aspiration or reflux at the time of pH testing, which carries a high risk of false representation of NGT placement. Similarly, distal migration of the NGT to the level of the pylorus or beyond can also result in difficulty obtaining a gastric sample to test pH for accurate gastric placement. Although the use of pH measurement for tube tip verification is the best evidence-based method, there are issues—as outlined above—that need to be considered.

Other Methods Used for NGT Verification

The use of an electromagnetic sensor-guided device for NGT placement verification in pediatric patients is controversial. A PSA issued in the United Kingdom described 2 patient deaths associated with the use of an electromagnetic sensor-guided device.⁴¹ The PSA mandates gastric pH measurement to accompany the use of the electromagnetic sensor-guided device to verify NGT placement. A limitation associated with this device is tube size. Currently, the smallest tube that accompanies the device is 8 French, which is often too large for many pediatric patients. Also, the external sensor necessary for use with the device may be too large and too heavy to be placed on the chest of smaller infants and children. Safety concerns with the use of the electromagnetic sensor-guided device include injury to the intestinal intima⁴² and inconsistency between the actual tube location and the image projected by the device.^{43,44} A US Food and Drug Administration (FDA) alert issued in January 2018, regarding use of an electromagnetic sensor-guided device for NGT placement, recommends user training from the manufacturer with mandated competency in device operation, and use of an additional method of NGT location verification.⁴⁵ Studies in the United States have demonstrated the use of an electromagnetic sensor-guided device to be helpful for the placement of transpyloric feeding tubes in adult and pediatric patients^{46,47}; however, definitive data for successful NGT placement in pediatric patients is limited.

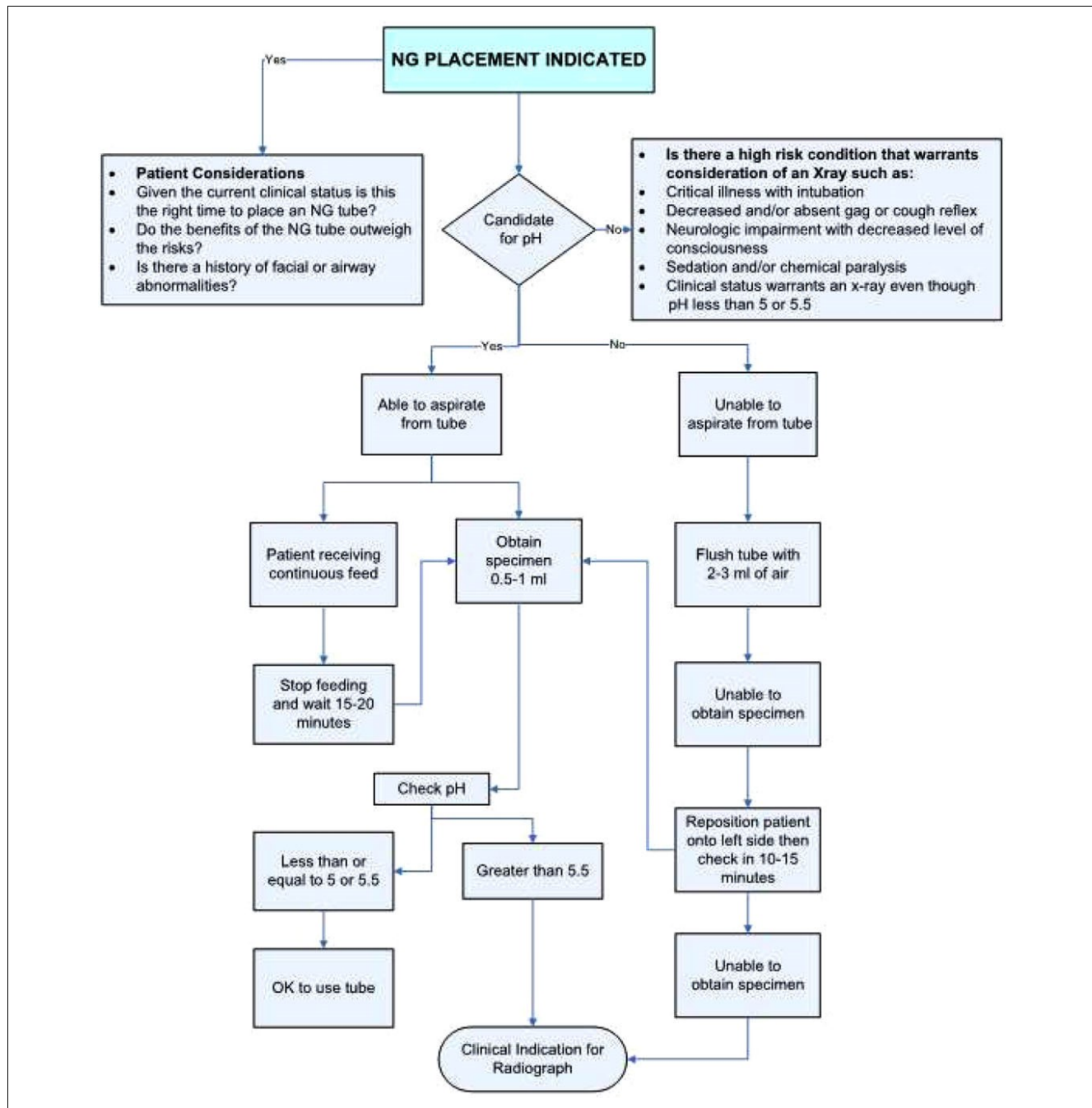


Figure 1. NGT placement and verification decision tree. NG, nasogastric.

The use of ultrasound technology as a noninvasive substitute for radiologic imaging to verify NGT placement shows promise. A recent study in a pediatric intensive care unit demonstrated 100% sensitivity with the use of ultrasound for correct placement of NGTs at the bedside when operated by a radiologist.⁴⁸ Further investigation into the feasibility and applicability of ultrasound to verify NGT location in children at the bedside by nonradiologists

is needed. Its portability, absence of radiation, and noninvasive properties make ultrasound a potentially useful method for verifying NGT location. An additional method for verification of NGT placement, capnography, has demonstrated enteral placement with 98% accuracy in one study⁴⁹; however, it is not currently recommended to be used as an independent method to verify NGT placement.

Recommendations

Based on the available evidence and as outlined in Figure 1, the following are recommendations for best practice standards to verify NGT location in pediatric patients:

- Provide education
 - Education should be provided for all clinicians placing NGTs within institutions and across care settings.
 - Education should include competency validation for placement, pH measurement, decision making to determine need for radiographic evaluation, documentation of tube placement, and patient tolerance of the procedure.
 - Competency-based education should be in place for providers interpreting radiographs to verify NGT placement.
- Use appropriate NGT placement and securing methods.
 - Use the Nose→Earlobe→Xiphoid process→Midline of the Umbilicus (NEMU) method for determination of NGT insertion length.
 - Document the centimeter marking on the tube, where it exits the nose or mouth, once correct tube placement is confirmed periodically depending on the policy of the healthcare setting.
 - In an NGT with a stylet in place prior to insertion, if the NGT has been flushed with sterile water to facilitate stylet lubrication and removal after insertion, aspirate the entire fill volume of sterile water and discard. A second aspiration is necessary to obtain gastric secretions for pH testing.
- Measure gastric pH.
 - Use gastric pH testing as the first-line method for NGT location verification.
 - A gastric pH value of 1–5.5 without a change in the patient’s clinical status is indicative of gastric placement.
 - When used intermittently for enteral feedings and/or medication administration, establish a schedule for frequency of NGT location confirmation.
 - When used continuously for enteral feeding, determine the need for frequency of confirmation with documentation of NGT location.
- Consider a radiograph for any patient in whom there is any concern for correct NGT placement, such as:

- Difficulty placing the NGT
 - NGT placement in any patient at high risk of misplacement. This includes those with known history of facial fractures, neurologic injury/insult/baseline abnormality, respiratory concerns, decreased or absent gag reflex, and those who are critically ill.
 - In any patient whose condition deteriorates shortly after NGT placement
- Improve interpretation and communication about the radiograph.
 - The radiograph requisition should clearly request “NGT placement verification” or similar language.
 - The radiograph report should contain a statement of the tube path, the location of the tube tip, and confirmation that the tube is positioned in the desired location and is appropriate for use.

Future Considerations

Challenges persist surrounding the placement and location verification of NGTs in pediatric patients. The following are potential solutions to be considered:

- Adoption of these recommendations with units and institutions implementing them to meet their specific needs
- Partnering with key stakeholders for technology and product development to allow for placement verification and reverification in real time for the duration of NGT use
- Research on best practice for ongoing reverification of correct NGT placement, including data on frequency of assessment for reverification of correct NGT location for patients on intermittent feedings and/or continuous feedings and/or NGT medication administration
- Standardized, mandated, state and federal reporting mechanisms for NGT misplacements, followed by a root cause analysis to evaluate the misplacement and to ascertain opportunities for improved education and practice

Conclusions

Placement of NGTs in pediatric patients to facilitate provision of EN, medication administration, and fluid infusion is a common practice performed by nurses without the use of technology. Despite the frequency of NGT placement, it carries the potential of patient harm if the tube is misplaced. Various methods for determining location verification exist. Radiography is the gold standard and measurement of

gastric pH is a validated method; however, there is no standardization in the United States on best practice for NGT location verification. The recommendations presented here are a necessary first step in establishing best practice related to NGT placement verification in the pediatric patient. The future considerations present numerous opportunities for collaboration between nurse scientists, clinicians, researchers, institutional leaders, policy makers, and industry partners to improve patient safety related to NGT placement and verification in children.

References

- Healthcare Cost and Utilization Project (HCUP). Overview of the National (Nationwide) Inpatient Sample (NIS). *Agency for Healthcare Research and Quality*. 2014. Available at: www.hcup-us.ahrq.gov/nisoverview.jsp. Accessed August 24, 2017.
- Lyman B, Kemper C, Northington L, et al. Use of temporary enteral access devices in hospitalized neonatal and pediatric patients in the United States. *JPEN J Parenter Enteral Nutr*. 2016;40:574–580.
- Cirgin Ellett ML, Cohen MD, Perkins SM, Smith CE, Lane KA, Austin JK. Predicting the insertion length for gastric tube placement in neonates. *J Obstet Gynecol Neonatal Nurs*. 2011;40:412–421.
- Ellett ML, Croffie JM, Cohen MD, Perkins SM. Gastric tube placement in young children. *Clin Nurs Res*. 2005;14:238–252.
- Baskin WN. Acute complications associated with bedside placement of feeding tubes. *Nutr Clin Pract*. 2006;21:40–55.
- Yardley IE, Donaldson LJ. Patient safety matters: reducing the risks of nasogastric tubes. *Clin Med (Lond)*. 2010;10:228–230.
- Daly W. Unusual complication of nasal intubation: report of case. *Anesthesiology*. 1953;14:96.
- Lind LJ, Wallace DH. Submucosal passage of a nasogastric tube complicating attempted intubation during anesthesia. *Anesthesiology*. 1978;49:145–147.
- Aronchick JM, Epstein DM, Gefter WB, Miller WT. Pneumothorax as a complication of placement of a nasogastric tube. *JAMA*. 1984;252:3287–3288.
- Bankier AA, Wiesmayr MN, Henk C, et al. Radiographic detection of intrabronchial malpositions of nasogastric tubes and subsequent complications in intensive care unit patients. *Intensive Care Med*. 1997;23:406–410.
- Metheny NA, Meert KL, Clouse RE. Complications related to feeding tube placement. *Curr Opin Gastroenterol*. 2007;23:178–182.
- Crisp CL. Esophageal nasogastric tube misplacement in an infant following laser supraglottoplasty. *J Pediatr Nurs*. 2006;21:454–455.
- Ellett ML, Cohen MD, Croffie JM, Lane KA, Austin JK, Perkins SM. Comparing bedside methods of determining placement of gastric tubes in children. *J Spec Pediatr Nurs*. 2014;19:68–79.
- De Espinosa H, García de Paredes C. Traumatic perforation of the pharynx in a newborn baby. *J Pediatr Surg*. 1974;9:247–248.
- Wynne DM, Borg HK, Geddes NK, Fredericks B. Nasogastric tube misplacement into Eustachian tube. *Int J Pediatr Otorhinolaryngol*. 2003;67:185–187.
- Arslantas A, Durmaz R, Cosan E, Tel E. Inadvertent insertion of a nasogastric tube in a patient with head trauma. *Childs Nerv Syst*. 2001;17:112–114.
- Creel AM, Winkler MK. Oral and nasal enteral tube placement errors and complications in a pediatric intensive care unit. *Pediatr Crit Care Med*. 2007;8:161–164.
- Glüer S, Schmidt AI, Jesch NK, Ure BM. Laparoscopic repair of neonatal gastric perforation. *J Pediatr Surg*. 2006;41:e57–58.
- Mattar MS, al-Alfy AA, Dahniya MH, al-Marzouk NF. Urinary bladder perforation: an unusual complication of neonatal nasogastric tube feeding. *Pediatr Radiol*. 1997;27:858–859.
- Wallace SC. Data Snapshot: Complications Linked to Iatrogenic Enteral Feeding Tube Misplacements. *PA Patient Saf Advis*. 2017;14:1–60.
- Kemper C, Northington L, Wilder K, Visscher D. A call to action: the development of enteral access safety teams. *Nutr Clin Pract*. 2014;29:264–266.
- National Health Service. Nasogastric tube misplacement: continuing risk of death and severe harm. *Patient Safety Alert*. 2016. NHS/PSA/RE/2016/006. Available at: <https://improvement.nhs.uk/news-alerts/nasogastric-tube-misplacement-continuing-risk-of-death-severe-harm/>. Accessed November 7, 2017.
- National Health Service. Placement devices for nasogastric tube insertion do not replace initial position checks. *Patient Safety Alert*. 2013. NHS/PSA/W/2013/001. Available at: <https://www.england.nhs.uk/wp-content/uploads/2013/12/psa-ng-tube.pdf>.
- Ellett ML, Cohen MD, Perkins SM, Croffie JM, Lane KA, Austin JK. Comparing methods of determining insertion length for placing gastric tubes in children 1 month to 17 years of age. *J Spec Pediatr Nurs*. 2012;17:19–32.
- Klasner AE, Luke DA, Scalzo AJ. Pediatric orogastric and nasogastric tubes: a new formula evaluated. *Ann Emerg Med*. 2002;39:268–272.
- Simons SR, Abdallah LM. Bedside assessment of enteral tube placement: aligning practice with evidence. *Am J Nurs*. 2012;112:40–46; quiz 48, 47.
- Irving SY, Lyman B, Northington L, Bartlett JA, Kemper C. Nasogastric tube placement and verification in children: review of the current literature. *Nutr Clin Pract*. 2014;29:267–276.
- (NACH) NACH. *Blind Pediatric NG Tube Placements Continue to Cause Harm*. Overland Park, KS: Child Health Patient Safety Organization, Inc.; 2012.
- Metheny N. AACN Practice Alert. Initial and ongoing verification of feeding tube placement in adults (applies to blind insertions and placements with an electromagnetic device). *Crit Care Nurse*. 2016;36(2):e8–e13.
- Metheny NA, Stewart BJ, Mills AC. Blind insertion of feeding tubes in intensive care units: a national survey. *Am J Crit Care*. 2012;21:352–360.
- Kleinerman RA. Cancer risks following diagnostic and therapeutic radiation exposure in children. *Pediatr Radiol*. 2006;36 Suppl 2:121–125.
- Cohen MD, Ellett M. Quality of communication: different patterns of reporting the location of the tip of a nasogastric tube. *Acad Radiol*. 2012;19:651–653.
- Rollins H, Arnold-Jellis J, Taylor A. How accurate are X-rays to check NG tube positioning? *Nurs Times*. 2012;108:14–16.
- Lee KH, Cho HJ, Kim EY, et al. Variation between residents and attending staff interpreting radiographs to verify placement of nutrition access devices in the neonatal intensive care unit. *Nutr Clin Pract*. 2015;30:398–401.
- Don S. Pediatric digital radiography summit overview: state of confusion. *Pediatr Radiol*. 2011;41:567–572.
- Gilbertson HR, Rogers EJ, Ukoumunne OC. Determination of a practical pH cutoff level for reliable confirmation of nasogastric tube placement. *JPEN J Parenter Enteral Nutr*. 2011;35:540–544.
- Stock A, Gilbertson H, Babl FE. Confirming nasogastric tube position in the emergency department. *Pediatr Emerg Care*. 2008;24:805–809.
- Metheny NA, Pawluszka A, Lulic M, Hinyard LJ, Meert KL. Testing placement of gastric feeding tubes in infants. *Am J Crit Care*. 2017;26:466–473.
- Kemper C, Haney B, Oschman A, et al. Use of pH testing to verify enteral feeding tube placement in neonates. Submitted to *Advances in Neonatal Care*, 2018.

40. Faden HS, Ma C. Trends in oral antibiotic, proton pump inhibitor, and histamine 2 receptor blocker prescription patterns for children compared with adults: implications for clostridium difficile infection in the community. *Clinical Pediatrics*. 2016;55: 712–716.
41. National Health Service. Nasogastric tube misplacement: continuing risk of death and severe harm. *Patient Safety Alert*. 2016. NHS/PSA/RE/2016/006. Available at: <https://improvement.nhs.uk/news-alerts/nasogastric-tube-misplacement-continuing-risk-of-death-severe-harm/>. Accessed March 20, 2018.
42. U.S. Food and Drug Administration. MAUDE – Manufacturer and user facility device experience. us department of health and human services. 2017. Available at: <https://www.accessdata.fda.gov/scripts/cdrh/cfdocs/cfmaude/search.cfm>. Accessed August 22, 2017.
43. Bryant V, Phang J, Abrams K. Verifying placement of small-bore feeding tubes: electromagnetic device images versus abdominal radiographs. *Am J Crit Care*. 2015;24:525–530.
44. Metheny NA, Meert KL. Update on effectiveness of an electromagnetic feeding tube-placement device in detecting respiratory placements. *Am J Crit Care*. 2017;26:157–161.
45. Drug USFa, (FDA) A, Division of Industry and Consumer Education. Feeding Tube Placement Systems, Letter to Health Care Providers. Silver Spring, MD: U.S. Food and Drug Administration 2018. Available at: <https://www.fda.gov/MedicalDevices/Safety/LetterstoHealthCareProviders/ucm591838.htm>.
46. Kline AM, Sorce L, Sullivan C, Weishaar J, Steinhorn DM. Use of a noninvasive electromagnetic device to place transpyloric feeding tubes in critically ill children. *Am J Crit Care*. 2011;20:453–459; quiz 460.
47. Brown AM, Perebza C, Handwork C, Gothard MD, Nagy K. Use of electromagnetic device to insert postpyloric feeding tubes in a pediatric intensive care unit. *Am J Crit Care*. 2017;26:248–254.
48. Atalay YO, Aydin R, Ertugrul O, Gul SB, Polat AV, Paksu MS. Does bedside sonography effectively identify nasogastric tube placements in pediatric critical care patients? *Nutr Clin Pract*. 2016.
49. Chau JP, Lo SH, Thompson DR, Fernandez R, Griffiths R. Use of end-tidal carbon dioxide detection to determine correct placement of nasogastric tube: a meta-analysis. *Int J Nurs Stud*. 2011;48: 513–521.