

Children's Mercy Kansas City

SHARE @ Children's Mercy

Manuscripts, Articles, Book Chapters and Other Papers

11-25-2019

The Early "Unnatural" History Following Surgical Repair of Ventricular Septal Defects.

Sathish M. Chikkabyrappa

Justin T. Tretter

Arpan R. Doshi
Children's Mercy Hospital

Sujatha Buddhe

Puneet Bhatla

See next page for additional authors

Let us know how access to this publication benefits you

Follow this and additional works at: <https://scholarlyexchange.childrensmercy.org/papers>



Part of the [Cardiology Commons](#), [Pediatrics Commons](#), and the [Surgery Commons](#)

Recommended Citation

Chikkabyrappa SM, Tretter JT, Doshi AR, Buddhe S, Bhatla P, Ludomirsky A. The Early "Unnatural" History Following Surgical Repair of Ventricular Septal Defects. *Kans J Med.* 2019;12(4):121-124. Published 2019 Nov 25.

This Article is brought to you for free and open access by SHARE @ Children's Mercy. It has been accepted for inclusion in Manuscripts, Articles, Book Chapters and Other Papers by an authorized administrator of SHARE @ Children's Mercy. For more information, please contact hlsteel@cmh.edu.

Creator(s)

Sathish M. Chikkabyrappa, Justin T. Tretter, Arpan R. Doshi, Sujatha Buddhe, Puneet Bhatla, and Achi Ludomirsky

The Early “Unnatural” History Following Surgical Repair of Ventricular Septal Defects

Sathish M. Chikkabyrappa, M.D.¹, Justin T. Tretter, M.D.²,
Arpan R. Doshi, M.D.³, Sujatha Buddhé, MBBS, M.S.¹,
Puneet Bhatla, M.D.⁴, Achi Ludomirsky, M.D.⁴

¹Seattle Children’s Hospital, University of Washington School of Medicine, Seattle, WA

²The Heart Institute, Cincinnati Children’s Hospital Medical Center, Cincinnati, OH

³Children’s Mercy Hospital, University of Kansas School of Medicine-Wichita, Wichita, KS

⁴New York University Langone Medical Center, New York, NY

Received March 14, 2019; Accepted for publication June 4, 2019; Published online Nov. 25, 2019

ABSTRACT

Introduction. Surgical outcomes for simple ventricular septal defects (VSD) have been excellent in the past three decades. For this project, the timing of resolution of left-sided dilation and mitral regurgitation (MR) following VSD repair was assessed.

Methods. Echocardiographic data surrounding surgery of 42 consecutive children who underwent surgical patch repair of a VSD were reviewed. The echocardiograms were reviewed up to a mean of 12 months post-operatively (range 9 - 14 months). Quantitative data indexed to body surface area including left atrial (LA) volume, mitral valve annulus diameter, and left ventricular end-diastolic dimension (LVEDD) was analyzed.

Results. The majority of our pre-surgical cohort had only trace (44%) or no MR (31%), with a small proportion having mild (16%) or moderate MR (9%). No patients had moderate or greater MR following repair at follow-up. The median mitral valve annular Z-score was 1.8 (SD 1.6; range: -1.2 to 4.1) pre-operatively, improving to a 0.6 (range: -1.7 to 2.4; $p < 0.001$) at follow-up. LA dilation was present in 70% of patients, with a median LA volume Z-score of 1.1 (range: -2.6 to 15.5), decreasing to 13% median Z-score -1.2 (range: -3.5 to 2.9; $p < 0.001$) at follow-up. LV dilation was present in 81% of pre-operative patients with a median LVEDD Z-score of 3.0 (range: -2.0 to 7.9). There was significant improvement in qualitative assessment of LV enlargement (25%) with a median LVEDD Z-score of 0.5 (range: -2.1 to 2.9; $p < 0.001$) at follow-up. Discharge echocardiogram was performed at a mean of 5.7 days (range: 3 - 12 days) following surgery.

Conclusions. Normalization of LA, mitral valve annulus, and LV size occurred within the first three months in the majority of patients, with significant changes occurring within the first post-operative week following surgical repair for VSD. *Kans J Med* 2019;12(4):121-124.

INTRODUCTION

Ventricular septal defects (VSD) occur in 5 to 50 per 1,000 live births, with isolated VSD comprising 20 - 30% of congenital heart

defects.¹ The clinical manifestations of VSD with resulting left to right shunt are dependent on the size of the defect and the relative pulmonary and systemic vascular resistances. Larger left to right shunts lead to pulmonary arterial and left-sided over-circulation, which can result in left ventricular (LV) dilation, leading to mitral annular dilation with resulting mitral regurgitation (MR) and left atrial (LA) dilation.^{1,2} Surgical repair is indicated in large shunts with a pulmonary to systemic blood flow ratio $> 2:1$ and associated congestive heart failure, failure to thrive despite optimal medical therapy, or with associated aortic insufficiency from a prolapsed aortic valve leaflet.³

The timing of surgical repair for a hemodynamically significant VSD commonly is performed at less than six months of age to avoid irreversible pulmonary arterial hypertension and myocardial damage from prolonged volume overload.⁴ Resolution of LV dysfunction from volume overload is reversible in these patients if repair is performed at an early age, with improvement in the degree of left heart dilation and MR noted within the first post-operative year.⁵ There are limited data regarding the timing of resolution of left heart dilation and LV dysfunction (both systolic and diastolic) along with variables such as bypass times, which may influence outcomes following surgical repair. The timing of resolution of associated MR, LA dilation, and LV enlargement following surgical repair for VSD were described in a cohort of pediatric patients at a single institution.

METHODS

A retrospective review was conducted of all patients, newborn to 18 years of age, who underwent surgical VSD closure from January 2008 to June 2014 at New York Langone Medical Center. Patients with other significant hemodynamic lesions were excluded (i.e., moderate-large atrial septal defects, moderate-severe aortic insufficiency, moderate-large patent ductus arteriosus). Immediate pre-surgical echocardiograms, along with post-surgical echocardiograms for up to one year following repair were reviewed. Echocardiographic data from prior reports regarding qualitative and quantitative measurements of chamber dilation, valve regurgitation, and ventricular function were recorded for all echocardiograms reviewed. LA volumes were measured using the prolate ellipse method.⁶

Mitral valve annulus diameters and LV dimensions in systole and diastole were recorded from both pre- and post-operative echocardiograms. The MV was measured in apical four chamber or parasternal long axis view during early diastole after the maximum excursion of leaflets from inner edge to inner edge at the hinge points of the leaflet attachments.⁷ The type of VSD was recorded as documented in the patient’s echocardiographic reports which often utilized the historical surgical nomenclature which had been used at New York University Langone Medical Center during the reviewed timeframe (perimembranous, outlet, inlet, or muscular). The VSD was not reclassified into the authors’ preferred nomenclature (the ICD-11 classification system) due to limited availability of the necessary images. However, we promote starting the classification with the borders of the defect; perimembranous, doubly committed, or muscular; and sub-classifying by right ventricular geography and the presence or absence of septal malalignment.⁸ Further characteristics of the VSD were recorded including the size as compared to the aortic annulus diameter (large

VSD > 1/2 diameter of aortic annulus, moderate VSD > 1/3 and < 1/2, and small VSD < 1/3), peak instantaneous Doppler gradient of the VSD, presence of right aortic cusp prolapse with resultant aortic insufficiency and presence of residual VSD following surgery.

Clinical information was recorded including demographics, body weight, height, body surface area, symptoms of heart failure prior to surgery, anti-congestive medication prior to surgery, electrocardiographic abnormalities, and surgical procedure notes including cardiopulmonary bypass time and any complications following surgery. Institutional review board approval for this retrospective review was obtained.

Statistical Analysis. The Statistical Package for Social Sciences (SPSS) version 20.0 (SPSS Inc., Chicago, IL, USA) was used for all data analyses. For variables with normal distribution, mean and standard deviation were reported. Variables without a normal distribution were expressed as median and ranges. The Student t-test was calculated for normally distributed continuous variables and the Wilcoxon signed ranks test was calculated for nonparametric variables. The Fisher exact test and one-way analysis of variance (ANOVA) were calculated for the MR category. A value of $p < 0.05$ determined statistical significance.

RESULTS

There were 42 patients meeting inclusion criteria with a median age of five months (range 0.1 - 14 years) who underwent VSD surgical repair. The echocardiograms were reviewed up to a mean of 12 months post-operatively (range 9 - 14 months). The study subjects had at least three echocardiograms post-operatively in the first 12 months with the initial echocardiogram performed within the first week, the second by approximately three months, and the third study performed around 9 - 12 months post-operatively. The most common type of VSD was perimembranous (70%), with equal distribution of the remaining VSD types. The majority of defects were classified as moderate to large in size based on the size of aortic valve annulus (moderate in 40%, large in 56%). Two-thirds of outlet VSD (doubly committed) patients had trace to mild aortic insufficiency on their preoperative echocardiogram without usual left heart dilation and congestive heart failure symptoms. Two-thirds of the study cohort additionally had one or more of the following: a patent foramen ovale, a small atrial septal defect, or a small patent ductus arteriosus.

The most common abnormal electrocardiogram finding was biventricular hypertrophy (71%). Two-thirds of patients had signs and symptoms of congestive heart failure (tachypnea, tachycardia, failure to thrive, and/or hepatomegaly) and were prescribed at least one anti-congestive medication (Table 1).

The MR was assessed qualitatively into trace, mild, moderate or severe. Nearly half of the pre-surgical cohort had trace MR (44%), followed by mild (16%) and moderate MR (9%), with no patients with severe MR. At three-month follow-up, two-thirds of the cohort had hemodynamically non-significant mitral regurgitation. There were no other anatomical abnormalities other than annular dilation. Forty-five percent of patients had a dilated mitral valve annulus pre-operatively with a mitral valve annular Z-scores > +2, which decreased to only 19% at follow-up. The pre-operative median mitral valve annular Z-score was 1.8 (range: -1.2 to 4.1), improving to

a Z-score of 0.6 (range: -1.7 to 2.4; $p < 0.001$) at follow-up (Figure 1). The median fractional shortening (FS) in the pre-operative echocardiogram was 36% (range: 31 - 59%). There was slight decrease in the median FS to 31% (range: 24 - 39%; $p < 0.001$) in the first post-operative echocardiogram likely due to sudden unloading of the LV volume. In the subsequent follow-up echocardiogram at three months, the median FS was 35% (range: 29 - 44%; $p < 0.001$ when compared to first post-op).

Table 1. Demographic data.

Total number of subjects	42
Age, mean years (range)	2 (0.1 - 14)
Sex (male)	43%
VSD types	
Perimembranous	70%
Muscular	10%
Inlet	10%
Outlet	10%
Size of the defect	
Large	56%
Moderate	40%
Small	4%
Additional cardiac lesions	
PFO/ASD	60%
PDA	7%
Abnormal EKG	71%
Heart failure	67%
Heart failure medications	69% Furosemide (n = 17); Furosemide and Digoxin (n = 9); Furosemide and Enalapril (n = 3)
Residual small VSD's	21%
Cardiopulmonary bypass times in minutes (mean)	65.9

ASD: atrial septal defect; EKG: electrocardiogram; PDA: patent ductus arteriosus; PFO: patent foramen ovale; VSD: ventricular septal defect.

Approximately 70% of pre-operative patients demonstrated LA dilation with a median LA volume Z-score of 1.1 (range: -2.6 to 15.5), improving to only 13% at follow-up with a median Z-score of -1.2 (range: -3.5 to 2.9; $p < 0.001$; Figure 2). The median difference in LA volume dimensions Z-score of 3.5 from pre-op to post-op echocardiogram demonstrates the sudden volume unloading following VSD closure. Few patients had normal pre-operative LA volumes, suggesting less of a volume overload. LA dilation is common in hemodynamically significant VSDs, however, it was not uncommon for a doubly committed VSD to be referred for surgery due to aortic regurgitation from aortic leaflet prolapse, rather than true left heart dilation. The LA volume Z-scores are normal to lower in this subset of population. The ultimate physiological effects of the majority of unrestricted VSDs are dilation of LA and LV.

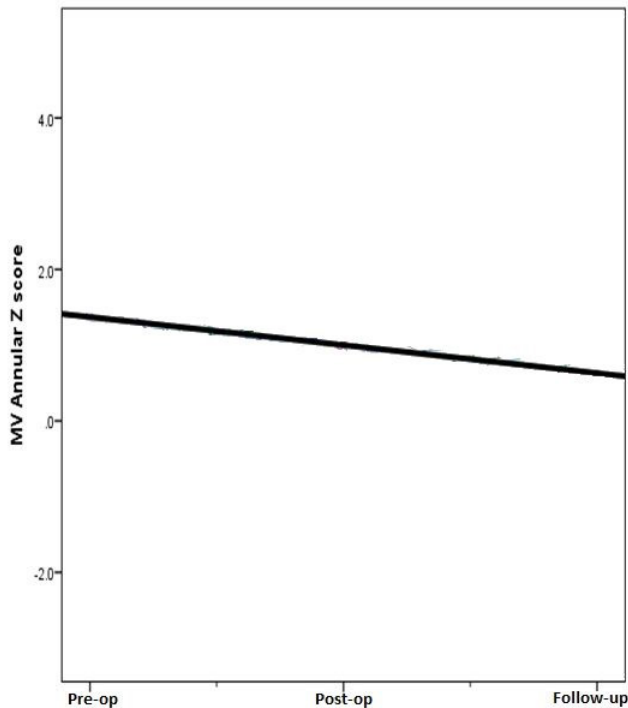


Figure 1. Mitral valve annulus Z-score surrounding ventricular septal defect surgical repair. The solid black slope represents the median change from pre-op to follow-up mitral valve Z-score (slope -0.4, $p = 0.02$).

In our pre-surgical cohort, LV enlargement was noted in 81% with a median LVEDD Z-score of 3.0 (range: -2.0 to 7.9). Immediate normalization of LV volume following surgery was uncommon, however, there was significant improvement in qualitative assessment of LV enlargement (25%) with a median LVEDD Z-score of 0.5 (range: -2.1 to 2.9; $p < 0.001$) at follow-up (Figure 3). The improvements in mean differences between mitral valve annular Z-score, LA volume, and LVEDD Z-score are displayed in Table 2. The majority of residual VSDs noted in the immediate post-operative period were no longer seen at the three-month follow-up echocardiogram and all were hemodynamically insignificant.

DISCUSSION

Although VSDs are one of the most common forms of congenital heart disease encountered, with surgical repair of VSD being one of the most common surgeries performed by congenital cardiothoracic surgeons, there is limited literature assessing the “unnatural” history of left heart dilation and its resolution following surgical repair. A similar study by Cho et al.⁹ reviewed pre- and post-operative echocardiographic data of 40 children who underwent surgical repair of VSD, noting that LA dilation was reduced within the first three months after surgical closure, with LV and mitral annular dilation decreasing within the first year. Our results showed a similar but more immediate trend in resolution of LA, mitral annular, and LV dilation, with persistence of some degree of MR into the early follow-up period. We assessed only short- to intermediate-term follow-up and did not correlate these changes to age, however, we hypothesized that the

majority of patients will have resolution of MR two to three years following surgical repair with quicker resolution in the younger patient.

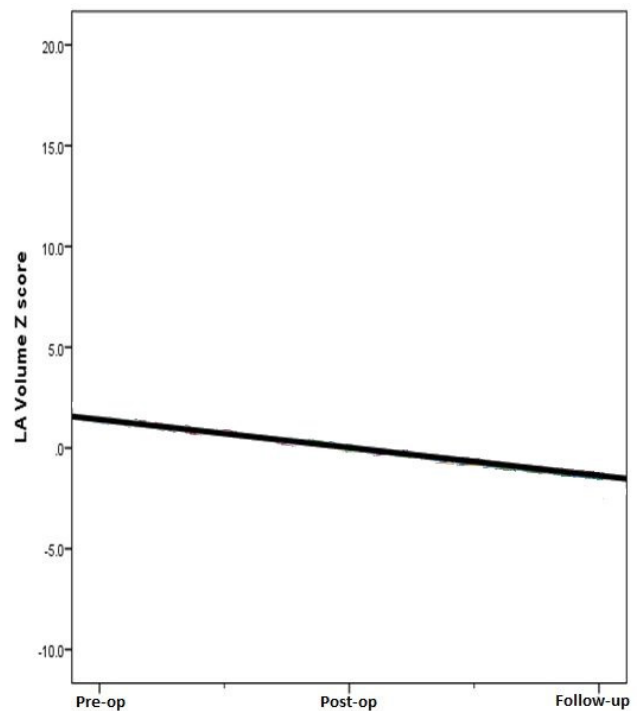


Figure 2. Left atrial volume Z-score surrounding ventricular septal defect surgical repair. The solid black slope represents the mean change from pre-op to follow-up LA volume Z-score (slope -1.4, $p = 0.01$).

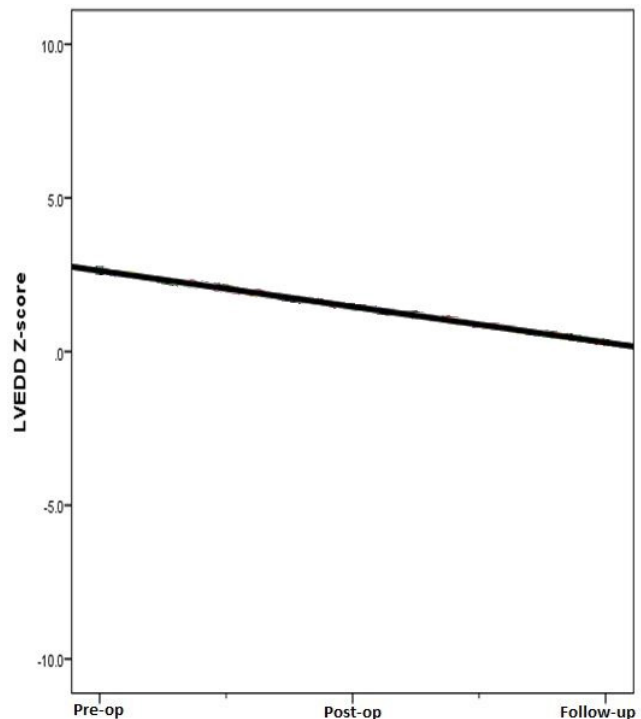


Figure 3. Left ventricular end-diastolic dimensions score surrounding ventricular septal defect surgical repair. The solid black slope represents the mean change from pre-op to follow-up LVEDD Z-score (slope -1.2, $p = 0.01$).

Table 2. Comparison of the change in median differences from pre-operative to post-operative to follow-up assessment.

	Pre-op to Post-op		Post-op to Follow-up		Pre-op to Follow-up	
	Median Difference	p value	Median Difference	p value	Median Difference	p value
MV Annular Z-score	2.8	< 0.001	0.0	0.9	1.15	< 0.001
LA Volume Z-Score	3.5	< 0.001	-0.6	0.001	2.28	< 0.001
LVEDD Z-Score	2.15	< 0.001	0.3	0.9	2.5	< 0.001

LA: left atrium; LVEDD: left ventricular end-diastolic dimension; MV: mitral valve.

In addition to assessing the course of left heart dilation and MR following surgical repair, we also assessed the degree of systolic and diastolic dysfunction in this cohort surrounding surgery. LV systolic function has been reported to normalize within one year following surgical repair of VSD, while normalization of RV systolic function may remain significantly impaired for up to 20 months post-operatively.¹⁰ Additionally, resulting right bundle branch block (RBBB) following surgical repair may affect right ventricular systolic and diastolic function, as well as LV diastolic function; however, LV systolic function appears to be unrelated to the presence of post-operative RBBB.^{11,12} Our experience demonstrated pre- and post-operative preservation of LV systolic function in most isolated VSD cases. Diastolic assessment was limited with the majority of cases only having mitral valve inflow Doppler patterns available and normal E (a ratio both pre- and post-operatively for age). Additionally, quantitative right ventricular systolic functional assessment was often not available, making it difficult to come to any conclusion regarding this parameter.

Although this investigation shed a positive light on the timely resolution of left heart dilation with preservation of ventricular function on what historically has been considered a relatively benign form of congenital heart disease, recent studies have focused on long-term morbidity following surgical repair of VSD. Although exercise capacity appears normal during childhood and adolescence following surgical repair of VSD,¹³ exercise intolerance has been demonstrated in early adulthood in these patients when compared to normal healthy controls.^{14,15} These findings illuminated the misconception that repaired VSD are a benign group of patients, and highlight the necessity for long-term follow-up extending into the adult years.

Study Limitations. Obvious limitations to this study were its retrospective design and small sample size, with only short- to intermediate-term follow-up. These findings are largely dependent on reported echocardiographic data; some are largely subjective, such as grading of the degree of mitral regurgitation, with follow-up studies often being limited, especially with regard to diastolic functional assessment.

CONCLUSIONS

Normalization of LA, mitral valve annulus, and LV size occurred within the first three months in the majority of children following surgical repair of VSD, with significant improvements occurring

within the first post-operative week in a large proportion of these children. Although complete resolution of MR was not demonstrated on intermediate follow-up in most patients, there was a trend toward improvement with resolution likely occurring on more long-term follow-up.

REFERENCES

- Rubio AE, Lewin MB. Ventricular Septal Defects. In: Allen HD, Driscoll DJ, Feltes TF, Shaddy RE (Eds.). *Moss and Adams' Heart Disease in Infants, Children, and Adolescents*. 8th Edition. Philadelphia, PA: Lippincott Williams & Wilkins, 2013; pp. 713-721. ISBN: 1451118937.
- Senzaki H, Kumakura R, Ishido H, Masutani S, Seki M, Yoshida S. Left atrial systolic force in children: Reference values for normal children and changes in cardiovascular disease with left ventricular volume overload or pressure overload. *J Am Soc Echocardiogr* 2009; 22(8):939-946. PMID: 19553083.
- Jonas R. Ventricular Septal Defect. In: Jonas R (Ed.). *Comprehensive Surgical Management of Congenital Heart Disease*. London, UK: Hooper Arnold Publication, 2004; pp. 242-255. ISBN: 1444112155.
- Pacileo G, Pisacane C, Russo MG, et al. Left ventricular mechanics after closure of ventricular septal defect: Influence of size of the defect and age at surgical repair. *Cardiol Young* 1998; 8(3):320-328. PMID: 9731646.
- Yoshikawa M, Sato T. Left ventricular end-systolic wall stress to volume relationship before and after surgical closure of ventricular septal defect. *Pediatr Cardiol* 1987; 8(2):93-98. PMID: 3628075.
- Ujino K, Barnes ME, Cha SS, et al. Two-dimensional echocardiographic methods for assessment of left atrial volume. *Am J Cardiol* 2006; 98(9):1185-1188. PMID: 17056324.
- Lopez L, Colan SD, Frommelt PC, et al. Recommendations for quantification methods during the performance of a pediatric echocardiogram: A report from the Pediatric Measurements Writing Group of the American Society of Echocardiography Pediatric and Congenital Heart Disease Council. *J Am Soc Echocardiogr* 2010; 23(5):465-495. PMID: 20451803.
- Franklin RCG, Béland MJ, Colan SD, et al. Nomenclature for congenital and paediatric cardiac disease: The International Paediatric and Congenital Cardiac Code (IPCCC) and the Eleventh Iteration of the International Classification of Diseases (ICD-11). *Cardiol Young* 2017; 27(10):1872-1938. PMID: 29286277.
- Cho HJ, Ma JS, Cho YK, Ahn BH, Na KJ, Jeong IS. Timing in resolution of left heart dilation according to the degree of mitral regurgitation in children with ventricular septal defect after surgical closure. *J Pediatr (Rio J)* 2014; 90(1):71-77. PMID: 24140379.
- Klitsie LM, Kuipers IM, Roest AA, et al. Disparity in right vs left ventricular recovery during follow-up after ventricular septal defect correction in children. *Eur J Cardiothorac Surg* 2013; 44(2):269-274. PMID: 23407159.
- Pedersen TA, Andersen NH, Knudsen MR, Christensen TD, Sørensen KE, Hjortdal VE. The effects of surgically induced right bundle branch block on left ventricular function after closure of the ventricular septal defect. *Cardiol Young* 2008; 18(4):430-436. PMID: 18577304.
- Karadeniz C, Atalay S, Demir F, et al. Does surgically induced right bundle branch block really effect ventricular function in children after ventricular septal defect closure? *Pediatr Cardiol* 2015; 36(3):481-488. PMID: 25293427.
- Binkhorst M, van de Belt T, de Hoog M, van Dijk A, Schokking M, Hopman M. Exercise capacity and participation of children with a ventricular septal defect. *Am J Cardiol* 2008; 102(8):1079-1084. PMID: 18929713.
- Menting ME, Cuypers JA, Opić P, et al. The unnatural history of the ventricular septal defect: Outcome up to 40 years after surgical closure. *J Am Coll Cardiol* 2015; 65(18):1941-1951. PMID: 25953746.
- Heiberg J, Petersen AK, Laustsen S, Hjortdal VE. Abnormal ventilator response to exercise in young adults operated for ventricular septal defect in early childhood: A long-term follow-up. *Int J Cardiol* 2015; 194:2-6. PMID: 26011258.

Keywords: ventricular heart septal defect, congenital heart defect, mitral regurgitation, dilations, pediatrics