

Children's Mercy Kansas City

SHARE @ Children's Mercy

Manuscripts, Articles, Book Chapters and Other Papers

2-17-2023

Disseminated Juvenile Xanthogranuloma with a Novel MYH9-FLT3 Fusion Presenting as a Blueberry Muffin Rash in a Neonate.

Emily E. Clark

Mollie Walton

Children's Mercy Kansas City

Lionel M L Chow

J Todd Boyd

M David Yohannan

See next page for additional authors

Let us know how access to this publication benefits you

Follow this and additional works at: <https://scholarlyexchange.childrensmercy.org/papers>



Part of the [Pediatrics Commons](#)

Recommended Citation

Clark EE, Walton M, Chow LML, Boyd JT, Yohannan MD, Arya S. Disseminated Juvenile Xanthogranuloma with a Novel MYH9-FLT3 Fusion Presenting as a Blueberry Muffin Rash in a Neonate. *AJP Rep.* 2023;13(1):e5-e10. Published 2023 Feb 17. doi:10.1055/a-2015-1080

This Article is brought to you for free and open access by SHARE @ Children's Mercy. It has been accepted for inclusion in Manuscripts, Articles, Book Chapters and Other Papers by an authorized administrator of SHARE @ Children's Mercy. For more information, please contact hlsteel@cmh.edu.

Creator(s)

Emily E. Clark, Mollie Walton, Lionel M L Chow, J Todd Boyd, M David Yohannan, and Shreyas Arya



Disseminated Juvenile Xanthogranuloma with a Novel MYH9-FLT3 Fusion Presenting as a Blueberry Muffin Rash in a Neonate

Emily E. Clark, APRN, NNP-BC¹ Mollie Walton, MD² Lionel M.L. Chow, MD, PhD³ J. Todd Boyd, DO⁴
M. David Yohannan, MD^{1,5} Shreyas Arya, MD^{1,5} 

¹ Department of Neonatology, Dayton Children's Hospital, Dayton, Ohio

² Department of Pediatric Cardiology, Children's Mercy Kansas City, Overland Park, Kansas

³ Department of Pediatric Hematology/Oncology, Wright State University Boonshoft School of Medicine and Dayton Children's Hospital, Dayton, Ohio

⁴ Department of Pathology and Laboratory Medicine, Wright State University Boonshoft School of Medicine and Dayton Children's Hospital, Dayton, Ohio

Address for correspondence Shreyas Arya, MD, Department of Neonatal-Perinatal Medicine, Wright State University Boonshoft School of Medicine and Dayton Children's Hospital, 1 Childrens Plaza, Dayton, OH 45404 (e-mail: shreyas703@gmail.com).

⁵ Department of Neonatal-Perinatal Medicine, Wright State University Boonshoft School of Medicine and Dayton Children's Hospital, Dayton, Ohio

AJP Rep 2023;13:e5–e10.

Abstract

Juvenile xanthogranuloma (JXG) is a benign proliferative histiocytic disorder of the dendritic cell phenotype. It mostly presents in the pediatric age group as a solitary skin lesion. We describe a rare case of an infant born with disseminated JXG who presented with a blueberry muffin rash at birth. A term infant was noted to have multiple petechiae, purple nodules, and macules (1 mm–2 cm in diameter) and hepatosplenomegaly, at the time of birth. Further investigations revealed thrombocytopenia and direct hyperbilirubinemia and a magnetic resonance imaging showed scattered tiny foci of restricted diffusion in multiple areas of the brain. Patient received multiple platelet transfusions in the first few weeks with gradual improvement in thrombocytopenia. Ultimately, a biopsy of one of the lesions revealed the diagnosis of disseminated JXG with notable atypical features. Somatic mutation analysis showed a novel MYH9-FLT3 fusion, but a bone marrow biopsy was negative. The lesions faded over time, relative to patient's growth and normal neurodevelopment was noted at 18 months of age. JXG should be considered in the differentials of blueberry muffin rash in an infant. Although, JXG is mostly a self-limited condition, congenital disseminated JXG may be associated with significant morbidity and mortality.

Keywords

- ▶ juvenile xanthogranuloma
- ▶ JXG
- ▶ MYH9-FLT3 fusion
- ▶ blueberry muffin rash
- ▶ neonate

Juvenile xanthogranuloma (JXG) is a benign proliferative disorder of histiocytes of the dendritic cell phenotype.¹ It is seen mostly in early childhood² and manifests as a self-limiting solitary reddish-brown to yellow papule or nodule with a preponderance for the head, neck, and upper trunk

region.¹ Even though exceedingly rare, JXG may present systemically with multiple disseminated cutaneous and/or extracutaneous lesions.³ While JXG is typically diagnosed clinically, a skin biopsy for histology and immunohistochemistry may be used for confirmation.⁴

received
December 13, 2022
accepted after revision
December 19, 2022
accepted manuscript online
January 18, 2023

DOI <https://doi.org/10.1055/a-2015-1080>.
ISSN 2157-6998.

© 2023. The Author(s).

This is an open access article published by Thieme under the terms of the Creative Commons Attribution-NonDerivative-NonCommercial-License, permitting copying and reproduction so long as the original work is given appropriate credit. Contents may not be used for commercial purposes, or adapted, remixed, transformed or built upon. (<https://creativecommons.org/licenses/by-nc-nd/4.0/>)

Thieme Medical Publishers, Inc., 333 Seventh Avenue, 18th Floor, New York, NY 10001, USA

Table 1 Differential diagnosis of blueberry muffin rash in newborn⁶⁻⁸

Infection
• Toxoplasma
• Rubella
• Cytomegalovirus
• Herpes simplex virus
• Coxsackie virus
• Parvovirus
• Epstein-Barr virus
• Syphilis
Neoplasm
• Congenital leukemia cutis
• Neuroblastoma
• Rhabdomyosarcoma
• Histiocytic disorders (Langerhans cell histiocytosis and disseminated JXG)
Hematologic
• Hemolytic disease of the newborn (ABO or Rh incompatibility)
• Hereditary Spherocytosis
• Severe fetal anemia (intracranial bleeding, twin-to-twin transfusion, fetal-maternal hemorrhage)
Congenital vascular lesions
• Disseminated neonatal hemangiomatosis
• Multifocal lymphangioendotheliomatosis
• Blue rubber bleb nevus syndrome
• Multiple glomangiomas
Other
• Neonatal lupus erythematosus
• Mastocytosis/Mastocytoma
• Urticaria pigmentosa

Abbreviation: JXG, juvenile xanthogranuloma.

The term “blueberry muffin rash” was first used in the 1960s, to describe the classic bluish-red maculopapular rash on the skin of a neonate with congenital rubella and represented sites of dermal hematopoiesis.⁵ However, this presentation can be caused by a wide variety of etiopathologies beyond just infection, including conditions causing severe fetal anemia, multifocal vascular lesions, and neoplastic processes (► **Table 1**).⁶⁻⁸ We describe a rare case of neonate presenting with a blueberry muffin rash at birth, which was caused by congenital disseminated JXG with a novel MYH9-FLT3 fusion.

Case Description

A 3,015-g male infant was born at 37 weeks' gestation via spontaneous vaginal delivery to a 26-year-old gravida 3, para

3 mother who received good prenatal care. Pregnancy was uncomplicated and maternal serologies were significant for a borderline rubella titer. Infant had Apgar scores of 8 and 9 at 1 and 5 minutes, respectively. At the time of delivery, infant was noted to have multiple petechiae, non-blanching purple nodules, and macules ranging from 1 mm to 2 cm in diameter (► **Fig. 1**). These lesions were scattered across his face, torso, and extremities. A thorough physical examination also revealed hepatosplenomegaly. A complete blood cell count, obtained at the birth hospital, was significant for a platelet count of 18,000/mm³ and a complete metabolic panel was significant for direct hyperbilirubinemia of 1 mg/dL. The infant received intramuscular vitamin K, erythromycin eye prophylaxis, and hepatitis B vaccine and was then transferred to a tertiary care facility for further evaluation of his rash, petechiae, thrombocytopenia, and direct hyperbilirubinemia.

Upon admission, a head ultrasound to rule out an intracranial bleed and an abdominal ultrasound to rule out an intra-abdominal mass were obtained and were normal. Liver was noted to be of normal homogenous echogenicity, and the gallbladder showed an echogenic nonshadowing structure compatible with biliary sludge. The infant was transfused 15 mL/kg of platelets (► **Fig. 2**) and pediatric hematology and infectious disease specialists were consulted. Workup for infectious etiologies including a blood culture, qualitative cytomegalovirus (CMV) urine polymerase chain reaction (PCR), rubella immunoglobulin M (IgM), toxoplasmosis IgM, herpes simplex virus blood PCR, rapid plasma reagin, severe acute respiratory syndrome coronavirus 2 nasopharyngeal PCR, and histoplasma antibody titers (due to family ownership of chickens) were obtained and negative.

However, qualitative CMV blood PCR was positive. Due to the discrepancy between the qualitative urine and blood CMV PCR results, a quantitative blood CMV PCR was obtained, and the infant was started on intravenous ganciclovir, which was later switched to oral valganciclovir, when he started tolerating enteral feeds. Infant passed an auditory brainstem response test, and an ophthalmologic examination (MRI) showed scattered tiny foci of restricted diffusion throughout the supratentorial white matter, left basal ganglia, left thalamus, and scattered tiny areas of susceptibility artifact in the cerebellum that were thought to be areas of hemorrhage.

Neonatal alloimmune thrombocytopenia testing was negative and platelet counts did not respond to intravenous immunoglobulin treatment on two separate occasions (► **Fig. 2**). He also developed severe neutropenia which was thought to be secondary to valganciclovir treatment and it remained persistent despite holding a few doses, so he received granulocyte colony stimulating factor (G-CSF) treatment. Once the absolute neutrophil count improved above 1,500/mm³, G-CSF was stopped. Urine homovanillic acid and vanillylmandelic acid levels were normal, ruling out neuroblastoma.

At this time, decision was made to biopsy a large 3-cm diameter lesion on the right distal thigh (► **Fig. 3**) which revealed the diagnosis of congenital disseminated JXG. The

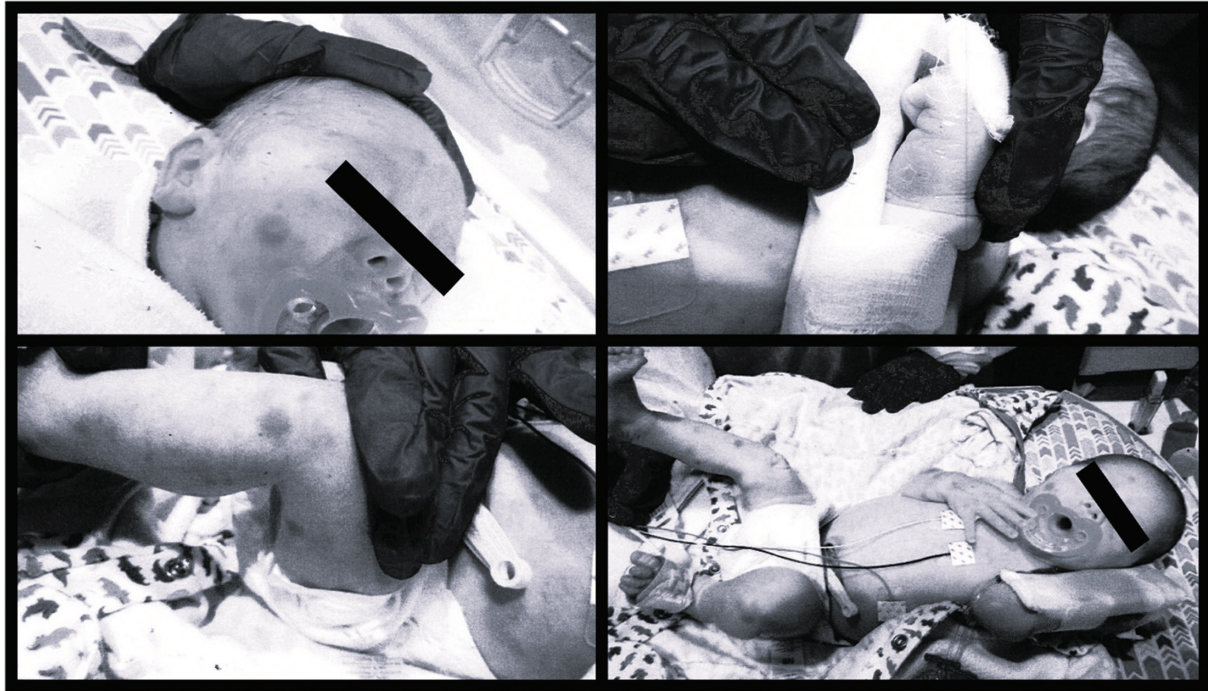

Fig. 1 Photo panel representing appearance of lesions at birth.

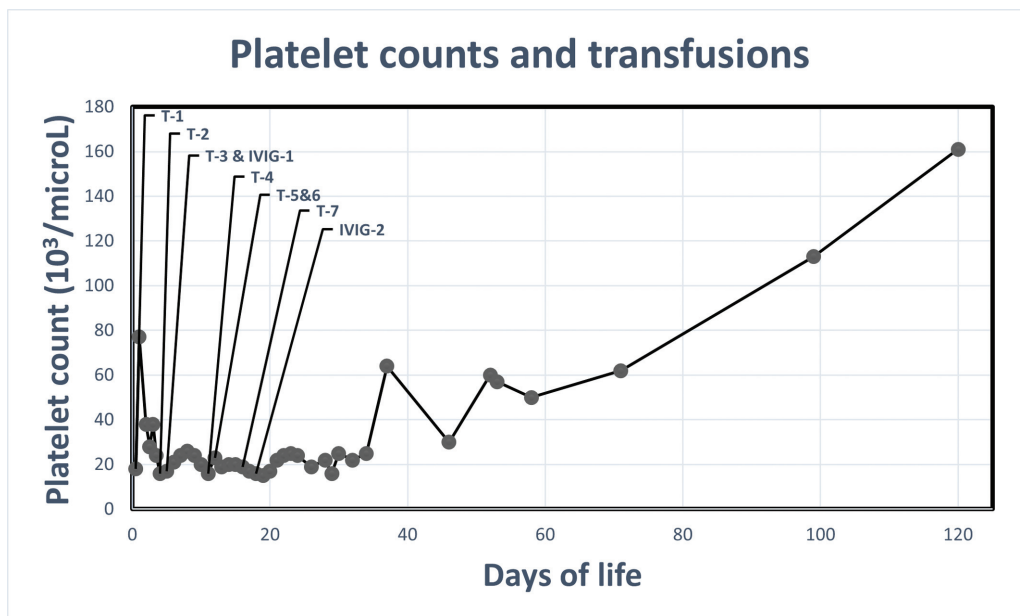


Fig. 2 Platelet counts from birth to 4 months of life. T-(n) represents platelet transfusions and IVIG-(n) represents intravenous immunoglobulin.

biopsy showed a monomorphic histiocytic infiltrate, which in areas had a vacuolated cytoplasm, with scattered multinucleated giant cells. Notable atypical features included a deep infiltrative growth pattern and increased proliferation, but no atypical mitosis or high-grade morphologic features were seen. Immunostaining showed diffuse expression of factor XIIIa, CD163, and CD68 stains, but the lesion was negative for CD1a stain (–Fig. 4). Additionally, anaplastic lymphoma kinase (ALK) immunostain and BRAF mutant-

specific immunostain (BRAF V600E) were also negative. CMV immunostain was negative for viral inclusions and the quantitative blood CMV PCR was negative, so valganciclovir was stopped.

Due to the unique presentation of JXG in this patient, somatic mutation analysis of the tumor was done which showed a novel MYH9-FLT3 fusion. A bone marrow biopsy was also performed at around 2 weeks of age, which showed no clonal proliferation with trilineage hematopoiesis. The

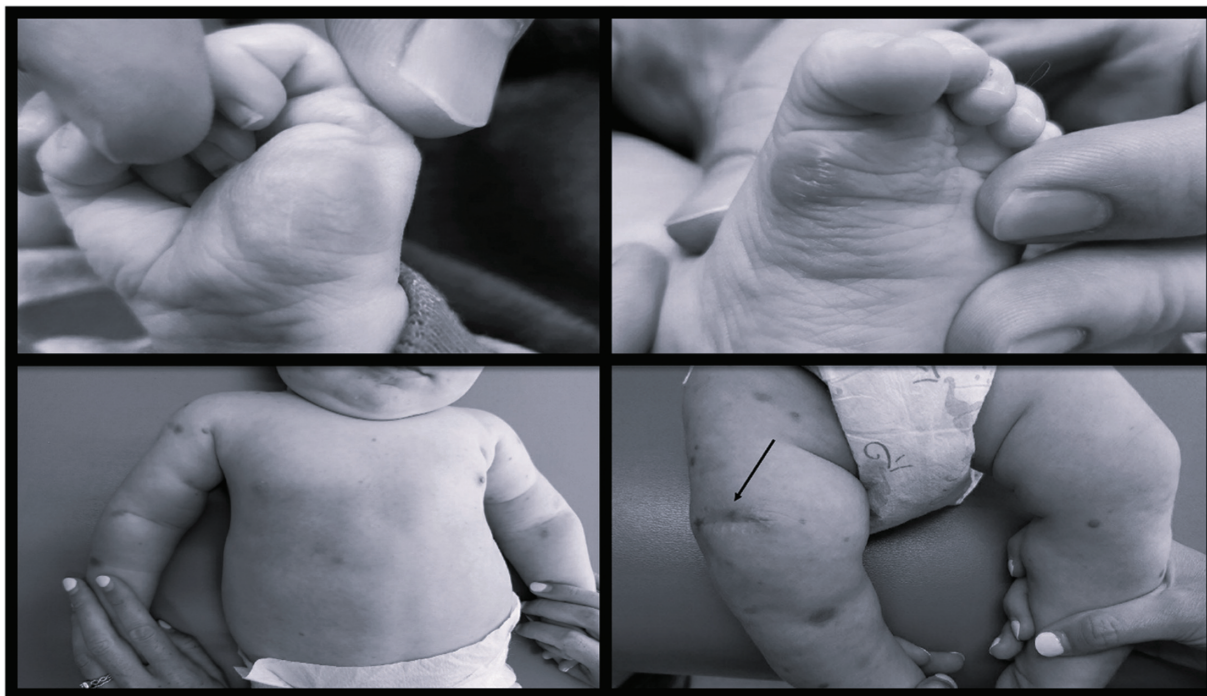

Fig. 3 Top panel represents appearance of hand and foot lesions at 2 months of age and bottom panel represents appearance of lesions at 6 months of age. Arrow points to the site of the biopsy of a large 3-cm diameter lesion on the right distal thigh which revealed the diagnosis.

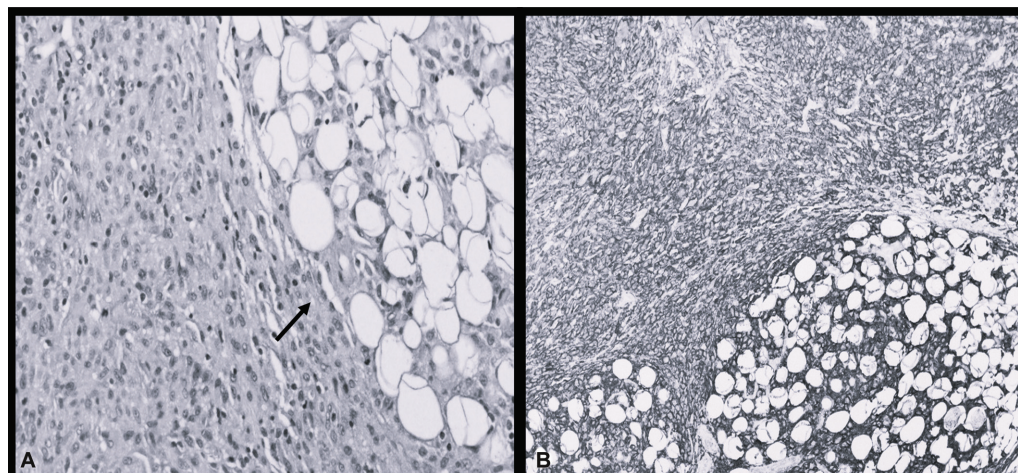


Fig. 4 (A) High power view with hematoxylin and eosin (H&E) stain demonstrating dense infiltrate of mononuclear histiocytic cells, some with a vacuolated cytoplasm, with extension into subcutaneous fat (black arrow). (B) Lesion was uniformly positive for CD163 immunostain confirming its histiocytic origin. The lesion was also positive for factor XIIIa and CD68 stains (not displayed).

erythroid and myeloid maturation was intact without any dysplasia; however, there was an increase in the megakaryocytic precursors by 50% and there was also evidence of dysmegakaryopoiesis.

During the hospital stay, the lesions remained stable in size and the platelet count remained low, but stable, despite multiple platelet transfusions (►Fig. 2). The infant also received multiple packed red blood cell transfusions due to severe anemia secondary to multiple laboratory draws. Direct hyperbilirubinemia gradually improved and an MRI prior to discharge showed stable scattered foci of hemosid-

erin deposition which were similar to the previous scan with no areas of restricted diffusion. At the time of discharge, around 1 month of age, the infant was direct breast feeding with good weight gain. He was followed closely by a hematologist oncologist outpatient and his thrombocytopenia gradually improved by 4 months of age (►Fig. 2).

The lesions slowly started fading in color and their growth was negligible compared with the relative growth of the patient (►Fig. 3). A bone marrow biopsy repeated around 1 year of age showed normal morphology and trilineage maturation. Flow cytometry did not show any abnormal

immunophenotypes and bone marrow sequencing did not show the MYH9-FLT3 fusion present in the JXG lesions. The patient was noted to have normal neurodevelopmental milestones at 18 months of age.

Discussion

JXG is the most common non-Langerhans cell histiocytosis (LCH)¹ and presents mostly as a single skin lesion in early childhood. However, it can also present with extensive systemic involvement with lesions disseminated in the deep soft tissues, liver, spleen, lungs, bone, bone marrow, or brain.³ Disseminated JXG has some striking similarities to LCH in that they are both histiocytic disorders that present in the neonatal period and can be associated with significant morbidity and mortality⁹; however, the distinguishing clinical feature of JXG is its greater potential for spontaneous resolution, usually in 1 to 5 years.^{1,9}

The histologic appearance of JXG depends on its location and age of presentation.¹⁰ Early cutaneous JXG is characterized by a dense mononuclear histiocytic infiltrate, similar to LCH. As time progresses, this is replaced by more vacuolated histiocytes and Touton giant cells, which were seen in our case (→Fig. 4). Touton giant cells are multinucleated cells with a foamy cytoplasm due to their high lipid content. However, these cells may be absent in extracutaneous JXG.¹ Eventually transitional or regressing JXG shows progressive fibrosis.² In the presence of considerable clinical and histologic overlap between disseminated JXG and LCH in neonates, immunohistochemistry is vital in distinguishing these entities. JXG is consistently positive for factor XIIIa, CD163, and CD68¹ but negative for S100 and CD1a stains, which are specific to LCH.¹⁰

JXG has also been described in association with neurofibromatosis type 1 and juvenile myelomonocytic leukemia.¹¹ While genetic mutations are not commonly seen in solitary lesions of JXG, a significant number of genetic alterations have been described with disseminated systemic JXG, namely ALK translocation, BRAF V600E mutation, and mutations in the genes involved in the MAPK pathway.^{12,13} Genomic analysis of the lesion in our patient was negative for these mutations but showed a novel MYH9-FLT3 fusion. FLT3 rearrangements have been reported with myeloid and lymphoid neoplasms with eosinophilia, with a high sensitivity in vitro to tyrosine kinase inhibitors,¹⁴ but the specific partner (MYH9) identified in this case has not been previously reported to be rearranged with FLT3 in any other neoplasm.

The treatment of JXG is dependent on the involved sites. Majority of JXG involving cutaneous, subcutaneous, and soft tissues is self-limiting and regresses spontaneously without scarring; however, some larger lesions may develop atrophic scarring.¹⁵ Systemic disseminated JXG may need treatment with excision or a combination of radiotherapy and chemotherapy.¹⁶ Standard-of-care chemotherapeutic agents for LCH (vinblastine, prednisone, and mercaptopurine) are usually used for treating systemic JXG.¹⁶ There have also been reports of the successful use of cladribine

and cytarabine for the treatment of central nervous system JXG.^{17,18} Recently, disseminated JXG with specific genetic mutations have been targeted with tyrosine kinase inhibitors.¹⁹

The overall prognosis of JXG is good but a high degree of morbidity and mortality is associated with disseminated JXG in infants with extensive visceral involvement.¹⁰ Our patient showed gradual spontaneous regression of lesions and their growth was negligible compared with the relative growth of the patient, by 6 months of age (→Fig. 3). A bone marrow biopsy repeated around 1 year of age showed normal morphology and trilineage maturation. Flow cytometry did not show any abnormal immunophenotypes and bone marrow sequencing did not show the novel MYH9-FLT3 fusion present in the JXG lesions. The patient was noted to have normal neurodevelopmental milestones at 18 months of age.

Conclusion

Disseminated JXG should be considered in the differentials of a blueberry muffin rash in a neonate, once infectious and hematological etiologies have been ruled out. While JXG is mostly a benign condition with spontaneous resolution expected in most cases, disseminated JXG can be associated with significant morbidity and mortality in neonates. In the future, routine genomic analysis and targeted chemotherapy may be used to effectively treat and improve outcomes associated with disseminated JXG.

Conflict of Interest

None declared.

References

- Dehner LP. Juvenile xanthogranulomas in the first two decades of life: a clinicopathologic study of 174 cases with cutaneous and extracutaneous manifestations. *Am J Surg Pathol* 2003;27(05):579–593
- Hernandez-Martin A, Baselga E, Drolet BA, Esterly NB. Juvenile xanthogranuloma. *J Am Acad Dermatol* 1997;36(3 Pt 1):355–367, quiz 368–369
- Freyer DR, Kennedy R, Bostrom BC, Kohut G, Dehner LP. Juvenile xanthogranuloma: forms of systemic disease and their clinical implications. *J Pediatr* 1996;129(02):227–237
- Höck M, Zelger B, Schweigmann G, et al. The various clinical spectra of juvenile xanthogranuloma: imaging for two case reports and review of the literature. *BMC Pediatr* 2019;19(01):128
- Brough AJ, Jones D, Page RH, Mizukami I. Dermal erythroplasia in neonatal infants. A manifestation of intra-uterine viral disease. *Pediatrics* 1967;40(04):627–635
- Holland KE, Galbraith SS, Drolet BA. Neonatal violaceous skin lesions: expanding the differential of the “blueberry muffin baby”. *Adv Dermatol* 2005;21:153–192
- Darby JB, Valentine G, Hillier K, et al. A 3-week-old with an isolated “blueberry muffin” rash. *Pediatrics* 2017;140(01):e20162598
- Niemi AK, Lee HC. Newborn who has a rash. *Neoreviews* 2008;9(02):e88–e91
- Isaacs H Jr. Fetal and neonatal histiocytoses. *Pediatr Blood Cancer* 2006;47(02):123–129
- Janssen D, Harms D. Juvenile xanthogranuloma in childhood and adolescence: a clinicopathologic study of 129 patients from the

- Kiel Pediatric Tumor Registry. *Am J Surg Pathol* 2005;29(01):21–28
- 11 Murphy JT, Soeken T, Megison S, Perez E. Juvenile xanthogranuloma: diverse presentations of noncutaneous disease. *J Pediatr Hematol Oncol* 2014;36(08):641–645
 - 12 Xu J, Huang X, Wen Y, et al. Systemic juvenile xanthogranuloma has a higher frequency of ALK translocations than BRAFV600E mutations. *J Am Acad Dermatol* 2020:S0190-9622(20)32445-2
 - 13 Diamond EL, Durham BH, Haroche J, et al. Diverse and targetable kinase alterations drive histiocytic neoplasms. *Cancer Discov* 2016;6(02):154–165
 - 14 Troadec E, Dobbstein S, Bertrand P, et al. A novel t(3;13)(q13; q12) translocation fusing FLT3 with GOLGB1: toward myeloid/lymphoid neoplasms with eosinophilia and rearrangement of FLT3? *Leukemia* 2017;31(02):514–517
 - 15 Gianotti F, Caputo R. Histiocytic syndromes: a review. *J Am Acad Dermatol* 1985;13(03):383–404
 - 16 Stover DG, Alapati S, Regueira O, Turner C, Whitlock JA. Treatment of juvenile xanthogranuloma. *Pediatr Blood Cancer* 2008;51(01):130–133
 - 17 Rajendra B, Duncan A, Parslew R, Pizer BL. Successful treatment of central nervous system juvenile xanthogranulomatosis with cladribine. *Pediatr Blood Cancer* 2009;52(03):413–415
 - 18 Maintz L, Wenzel J, Irnich M, Reinhard H, Bieber T. Successful treatment of systemic juvenile xanthogranulomatosis with cytarabine and 2-chlorodeoxyadenosine: case report and review of the literature. *Br J Dermatol* 2017;176(02):481–487
 - 19 Eissa SS, Clay MR, Santiago T, et al. Dasatinib induces a dramatic response in a child with refractory juvenile xanthogranuloma with a novel MRC1-PDGFRB fusion. *Blood Adv* 2020;4(13):2991–2995