

Children's Mercy Kansas City

## SHARE @ Children's Mercy

---

Manuscripts, Articles, Book Chapters and Other Papers

---

3-2024

### Hypophosphatasia diagnosis: current state of the art and proposed diagnostic criteria for children and adults.

Aliya A. Khan

Maria Luisa Brandi

Eric T. Rush

*Children's Mercy Hospital*

Dalal S. Ali

Hatim Al-Alwani

*See next page for additional authors*

Let us know how access to this publication benefits you

Follow this and additional works at: <https://scholarlyexchange.childrensmercy.org/papers>

---

#### Recommended Citation

Khan AA, Brandi ML, Rush ET, et al. Hypophosphatasia diagnosis: current state of the art and proposed diagnostic criteria for children and adults. *Osteoporos Int.* 2024;35(3):431-438. doi:10.1007/s00198-023-06844-1

This Article is brought to you for free and open access by SHARE @ Children's Mercy. It has been accepted for inclusion in Manuscripts, Articles, Book Chapters and Other Papers by an authorized administrator of SHARE @ Children's Mercy. For more information, please contact [hlsteel@cmh.edu](mailto:hlsteel@cmh.edu).

---

**Creator(s)**

Aliya A. Khan, Maria Luisa Brandi, Eric T. Rush, Dalal S. Ali, Hatim Al-Alwani, Khulod Almonaei, Farah Alsarraf, Severine Bacrot, Kathryn M. Dahir, Karel Dandurand, Chad Deal, Serge Livio Ferrari, Francesca Giusti, Gordon Guyatt, Erin Hatcher, Steven W. Ing, Muhammad Kassim Javaid, Sarah Khan, Roland Kocijan, Agnes Linglart, Iman M'Hiri, Francesca Marini, Mark E. Nunes, Cheryl Rockman-Greenberg, Christian Roux, Lothar Seefried, Jill H. Simmons, Susan R. Starling, Leanne M. Ward, Liang Yao, Romina Brignardello-Petersen, and E Michael Lewiecki



# Hypophosphatasia diagnosis: current state of the art and proposed diagnostic criteria for children and adults

Aliya A. Khan<sup>1</sup> · Maria Luisa Brandi<sup>2,3</sup> · Eric T. Rush<sup>4,5,6</sup> · Dalal S. Ali<sup>1</sup> · Hatim Al-Alwani<sup>1</sup> · Khulod Almonaei<sup>1</sup> · Farah Alsarraf<sup>1</sup> · Severine Bacrot<sup>7</sup> · Kathryn M. Dahir<sup>8</sup> · Karel Dandurand<sup>9</sup> · Chad Deal<sup>10</sup> · Serge Livio Ferrari<sup>11</sup> · Francesca Giusti<sup>3</sup> · Gordon Guyatt<sup>12</sup> · Erin Hatcher<sup>13</sup> · Steven W. Ing<sup>14</sup> · Muhammad Kassim Javaid<sup>15</sup> · Sarah Khan<sup>16</sup> · Roland Kocijan<sup>17</sup> · Agnes Linglart<sup>18</sup> · Iman M'Hiri<sup>16</sup> · Francesca Marini<sup>2</sup> · Mark E. Nunes<sup>19</sup> · Cheryl Rockman-Greenberg<sup>20</sup> · Christian Roux<sup>21,22</sup> · Lothar Seefried<sup>23</sup> · Jill H. Simmons<sup>8</sup> · Susan R. Starling<sup>4</sup> · Leanne M. Ward<sup>24</sup> · Liang Yao<sup>12</sup> · Romina Brignardello-Petersen<sup>12</sup> · E. Michael Lewiecki<sup>25</sup>

Received: 29 December 2022 / Accepted: 23 June 2023 / Published online: 20 November 2023  
© Crown 2023

## Abstract

**Background** This manuscript provides a summary of the current evidence to support the criteria for diagnosing a child or adult with hypophosphatasia (HPP). The diagnosis of HPP is made on the basis of integrating clinical features, laboratory profile, radiographic features of the condition, and DNA analysis identifying the presence of a pathogenic variant of the tissue nonspecific alkaline phosphatase gene (*ALPL*). Often, the diagnosis of HPP is significantly delayed in both adults and children, and updated diagnostic criteria are required to keep pace with our evolving understanding regarding the relationship between *ALPL* genotype and associated HPP clinical features.

**Methods** An International Working Group (IWG) on HPP was formed, comprised of a multidisciplinary team of experts from Europe and North America with expertise in the diagnosis and management of patients with HPP. Methodologists (Romina Brignardello-Petersen and Gordon Guyatt) and their team supported the IWG and conducted systematic reviews following the GRADE methodology, and this provided the basis for the recommendations.

**Results** The IWG completed systematic reviews of the literature, including case reports and expert opinion papers describing the phenotype of patients with HPP. The published data are largely retrospective and include a relatively small number of patients with this rare condition. It is anticipated that further knowledge will lead to improvement in the quality of genotype-phenotype reporting in this condition.

**Conclusion** Following consensus meetings, agreement was reached regarding the major and minor criteria that can assist in establishing a clinical diagnosis of HPP in adults and children.

**Keywords** Diagnosis · Hypophosphatasia · Major criteria · Minor criteria

## Introduction

Hypophosphatasia (HPP) is a rare inherited metabolic disease which affects bones and teeth along with other systemic manifestations due to loss of function (LOF) mutations in the alkaline phosphatase gene (*ALPL*), encoding the tissue-nonspecific alkaline phosphatase (TNSALP) enzyme [1].

Currently, more than 400 different disease-causing variants in the *ALPL* gene have been identified [2]. The presentation of HPP can be extremely variable within and between families, in both children and adults. Patients at the severe end of the spectrum present with severe demineralization of the bones, pulmonary hypoplasia, respiratory failure, and vitamin B6-responsive seizures [3]. Patients at the mildest end of the spectrum present with only findings of tooth loss or periodontal disease [1, 4].

The diagnosis of HPP is often missed or delayed in children and particularly in adults. Data from the Global HPP Registry indicates that the median time between the onset

Aliya A. Khan, Maria Luisa Brandi, Eric T. Rush and Dalal S. Ali are shared first authors.

Extended author information available on the last page of the article

of symptoms and the diagnosis of HPP is 5.7 years [5]. During this time, individuals may suffer from significant multisystem complications of HPP. They may also be misdiagnosed and/or mistreated with drugs such as bisphosphonates, which may in fact further impair the underlying skeletal mineralization defect, increasing the risk of atypical femoral fractures (AFFs) in these patients. It is recognized that AFFs are associated with HPP in patients without exposure to bisphosphonates [6]. An early and timely diagnosis is critical to ensuring appropriate evaluation and treatment of the multisystem complications of HPP [7].

Molecular genetics is a rapidly evolving field and is still in its infancy. *ALPL* gene sequencing can confirm the diagnosis; however, the presence of a pathogenic variant in the *ALPL* gene is not seen in all patients with HPP and is not required to make the diagnosis.

## Pathophysiology

HPP manifestations are due to deficient activity of the TNSALP enzyme, which accounts for 95% of total alkaline phosphatase (ALP) activity. There are three tissue-specific alkaline phosphatases, namely the germ cell, intestinal, and placental ALP [1]. TNSALP is present in all tissues but is most abundant in the bone, liver, and kidneys [4]. TNSALP is an ectoenzyme that is attached to the outer surface of the osteoblast plasma membrane via a glycosyl inositol anchor (GPI) [8, 9]. TNSALP is a homodimer composed of 2 identical subunits; enzyme activity requires three metal binding sites, two of which are occupied by zinc and one by magnesium, and the third metal binding site is occupied by calcium [1, 10, 11]. TNSALP dephosphorylates many extracellular molecules, with the three major natural substrates for TNSALP being inorganic pyrophosphate (PPi), pyridoxal-5'-phosphate (PLP), and phosphoethanolamine (PEA) [12–15].

Inorganic pyrophosphate accumulates in the presence of deficient TNSALP activity, resulting in an altered ratio of phosphate to inorganic pyrophosphate, leading to mineralization defects in the bone and in the teeth [16, 17]. The skeletal manifestations of this mineralization defect can include rickets (lack of growth plate mineralization) in children and osteomalacia (lack of bone tissue mineralization) in both children and adults. As a result of the reduction in TNSALP activity and/or mineralization defects, there are myriad potential disease manifestations involving different organ systems, as described below.

The musculoskeletal (MSK) manifestations of HPP include chronic pain, decreased mobility, and calcium pyrophosphate crystal deposition in the joints, resulting in chondrocalcinosis or pseudogout [1]. Fractures and

pseudofractures are also relatively common, with 62.1% of patients having had at least one fracture or pseudofracture before treatment with enzyme replacement therapy [5]. Pseudofractures (AFF) have been proposed to be one of the hallmarks of HPP [6]. A case report described an AFF following exposure to bisphosphonate therapy in an adult with HPP [18]. HPP is a rare condition, and the vast majority of individuals with suppressed ALP on bisphosphonate therapy do not have underlying HPP. The suppressed ALP is due to bisphosphonate therapy [19].

The renal complications include nephrocalcinosis, which develops in association with the presence of multiple risk factors including hypercalcemia, hyperphosphatemia, as well as hypercalciuria. Nephrocalcinosis can contribute to declines in renal function [1].

As the skeleton is not being mineralized, due to the accumulation of PPi and an altered phosphate to PPi ratio, elevations in serum calcium may develop and may lead to suppression of parathyroid hormone (PTH) [1].

Significant neurologic manifestations and subsequent consequences result from the altered vitamin B6 metabolism. Pyridoxal-5'-phosphate, the active metabolite of vitamin B6, is dephosphorylated by TNSALP to form pyridoxal. Pyridoxal crosses the blood–brain barrier and in the brain is rephosphorylated to PLP, which is an essential cofactor for neurotransmitter (including Gamma-aminobutyric acid (GABA), serotonin, and dopamine) synthesis [1, 12, 13, 20, 21]. Depletion of vitamin B6 in the central nervous system (CNS) can result in seizures in some affected infants [2, 22]. TNSALP also affects the proliferation and differentiation of neural stem cells, as well as myelination and growth of axons and synapse maturation and maintenance [23, 24]. In adults, neuropsychiatric manifestations may be more subtle with fatigue, headache, depression, and anxiety [2].

In a retrospective chart review of 82 patients with HPP, fatigue was present in 66%, headache in 61%, sleep disturbance in 51%, gait abnormality in 44%, vertigo in 43%, depression in 39%, and anxiety was seen in 35% [22].

The dental manifestations include loss of alveolar bone and enlarged pulp chambers. Impaired mineralization of the cementum and the periodontal (PDL) ligament results in premature loss of the primary teeth by age 4 years. The tooth exfoliates with the root intact and may also have an abnormal shape, color, and structure. Periodontal disease is also an important manifestation of HPP [1, 2].

## Diagnosis of HPP

The diagnosis of HPP is a clinical diagnosis made on the basis of signs and symptoms as well as complications of HPP [1, 2, 4]. It is supported by a persistently low ALP

**Table 1** Causes of low alkaline phosphatase

Drugs	Anti-resorptive therapy [28] Chemotherapy [1] Excess vitamin D [1]
Endocrine disorders	Hypoparathyroidism [29, 30] Hypothyroidism [31] Hypercortisolism [32] Renal osteodystrophy and adynamic bone disease [33] Delayed growth and puberty
Hematological conditions	Pernicious anemia [34] Massive blood transfusions [1] Myeloproliferative disorders [1] Myeloma [35]
Nutritional deficiencies	Magnesium [31] Zinc Vitamin C B6, B12, and folate Protein/calorie Copper Celiac disease
Miscellaneous	Severe illness Major surgery or trauma Wilson's disease [36, 37] Achondroplasia [31] Disorders affecting linear growth in childhood
Laboratory factors	Use of EDTA* or citrate in test tube [26] Use of oxalate in test tube [26] Hemolysis [38]

Abbreviations: EDTA: Ethylenediaminetetraacetic acid

level adjusted for age and gender [7, 25]. A low ALP level requires further evaluation with the exclusion of other conditions or drugs which can contribute to a reduction in the ALP activity. These include drugs, such as anti-resorptive agents, excessive levels of vitamin D, as well as chemotherapy [1, 3]. Some diseases can also result in low ALP levels. These include hypoparathyroidism, hypothyroidism, hypercortisolism, renal osteodystrophy with adynamic bone disease, achondroplasia, Wilson's disease, and myeloma [1]. In children, any disorder which impairs linear growth has the potential to result in lower serum ALP levels, since markers of bone turnover are indeed influenced by linear growth [4]. This is such an important principle that when serum ALP levels are evaluated in children and adolescents, they are benchmarked to age- (or bone-age, if delayed) and sex-matched reference values (see Table 1).

Miscellaneous causes of low ALP include any severe illness or major surgery or trauma, massive transfusions, nutritional deficiencies, celiac disease, vitamin C deficiency, or zinc or magnesium deficiency [1]. As magnesium is an important cofactor for ALP, a low serum magnesium can reduce ALP activity [1].

There are also technical factors resulting in a low ALP level. The assay measures the activity of the enzyme not quantity. It is important to avoid test tubes containing

anticoagulants with ion chelating agents such as EDTA or oxalate as TNSAP requires Mg + 2 as a cofactor. The presence of EDTA or oxalate as an anticoagulant will bind to magnesium and decrease ALP activity [26]. It is necessary therefore to use heparin lithium as the anticoagulant in the test tube when measuring ALP levels. [27]. Confirming that the reduction in ALP is not due to another condition or drug is critical in following the diagnostic pathway.

## Imaging

Radiographs are of value in the assessment of individuals with a possible diagnosis of HPP [1]. A skeletal survey is helpful in identifying features of rickets or craniosynostosis in children [4]. Radiographs may also identify fractures and pseudofractures, which are a feature of osteomalacia, delayed fracture healing (classically in the metatarsals); chondrocalcinosis with calcium pyrophosphate deposition in and around the joints (hips, knees, and wrists) may also be evident on radiographs [39]. Radionuclide bone scan, magnetic resonance imaging (MRI), or computed tomography (CT) study may be required to further evaluate pseudofractures [1]. Renal ultrasound is helpful in determining the presence of nephrocalcinosis or nephrolithiasis [40, 41].

**Table 2** The biochemical characteristics of HPP and other metabolic bone diseases

	HPP[4, 47, 48]	Nutritional rickets [47–49]	X-linked hypophosphatemia (XLH) [48, 50–52]	Osteogenesis imperfecta (OI) [48]
Gene mutation	Loss of function mutation of the <i>ALPL</i> gene	N/A	Inactivating mutation in the <i>PHEX</i> gene	<i>Almost two dozen genes have been implicated in OI, most of which affect type I procollagen synthesis, processing, or mineralization</i>
Pathogenesis	Decreased activity of TNSALP	Inadequate intake of calcium and phosphate or malabsorption	Renal phosphate wasting secondary to increased FGF23 levels	Most cases of OI result from a defect in osteoblast function
Biochemical characteristics				
ALP	↓	↑	↑	Normal (or high in OI VI and/or following recent fractures)
Serum PLP or urine PEA	↑	N/A	↓ or normal	N/A
Calcium	↑ or normal	↓ or normal	Normal	Normal
Phosphate	↑ or normal	↓	↓	Normal
PTH	↓ or ↑ or normal	↑	Normal or ↑	Normal
25-hydroxy vitamin D	Normal	↓	Normal	Normal

Abbreviations: HPP hypophosphatasia, ALPL alkaline phosphatase gene, TNSALP tissue nonspecific alkaline phosphatase, ALP alkaline phosphatase, PLP pyridoxal 5' phosphate, PTH parathyroid hormone, PHEX phosphate-regulating gene with homologies to endopeptidases on the X chromosome, FGF23 fibroblast growth factor 23, N/A not available, ↑ high, ↓ low, PEA: Phosphoethanolamine

## Genetic studies

Genetic analysis of the *ALPL* gene and other phenotypically related genes (e.g., *COL1A1/COL1A2*) is of value in confirming the diagnosis [42, 43]. Based on the type of genetic testing performed, it should be confirmed whether deletion/duplication can be detected as a part of Next Generation Sequencing or if companion deletion/duplication testing is required. Current technology enables the evaluation of approximately 95% of the mutations currently documented [42, 43]. Genetic transmission may be autosomal dominant or recessive, and genetic counseling is helpful in identifying affected family members and for reproductive counseling [42].

Other skeletal conditions with similar presenting features should also be excluded. These include nutritional rickets and evaluating serum 25 hydroxyvitamin D will exclude the presence of vitamin D inadequacy (which can also be co-morbid in HPP). X-linked hypophosphatemia (XLH) is due to an inactivating mutation in the *PHEX* gene resulting in elevations in fibroblast growth factor 23 (FGF-23) and high urine phosphate losses. The ratio of tubular maximum phosphate reabsorption adjusted for GFR (TmP/GFR) is low and should be calculated in the presence of hypophosphatemia [44]. Osteogenesis imperfecta (OI) is a clinical diagnosis confirmed on DNA analysis in the majority of

**Table 3** Diagnostic clues to the presence of HPP

Recurrent fractures
Poorly healing fractures
Chondrocalcinosis
Nephrocalcinosis
Enthesopathies with calcification of the insertion sites for tendons and ligaments
Presence of musculoskeletal pain
Abnormal gait
Early loss of primary teeth, with the root intact
Abnormal tooth color or shape [53]

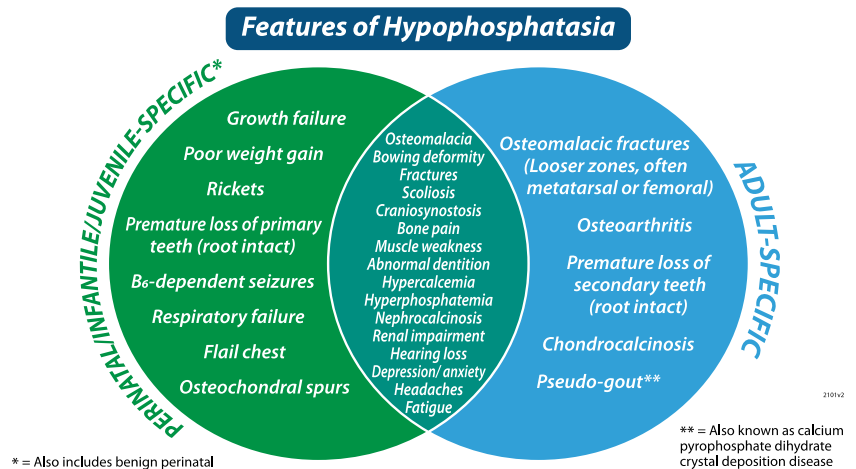
patients; serum ALP is usually normal in OI, although can be high in OI type VI, and in the setting of recent fractures [45, 46] (see summary (Table 2)).

## Diagnostic clues

The following are diagnostic clinical clues to the presence of HPP, which require careful evaluation (Table 3):

Features of HPP seen in the pediatric and adult patient population may overlap as noted below in Fig. 1

**Fig. 1** Features of HPP in the pediatric and adult patient population with some overlapping features between the two age groups



## Developing diagnostic criteria for HPP

As HPP is a rare disease, diagnosis is often delayed with a median time to diagnosis of 5.7 years ( $n = 194$ ) from the onset of first HPP signs and symptoms [5]. During this time, individuals experienced complications of the disease and may have been misdiagnosed with other conditions or received drug therapy which is contraindicated in the presence of HPP such as bisphosphonates.

An International Working Group (IWG) comprised of specialists with expertise in HPP and diagnosis and management in adults and children was formed in 2021. The IWG members were selected on the basis of their expertise and publications in the field and equal consideration was given to men and women as well as geographic representation. Methodologists were invited from McMaster University with expertise in developing guidelines using the GRADE approach. The methodology team completed a systematic review of the existing literature and evaluated 2 bodies of evidence to establish the major and minor criteria for the diagnosis of HPP (Brandi et al., Rush et al.). The first body of evidence consisted of expert opinion as noted from the authors of publications describing the diagnosis of HPP using any study design (reviews, case reports, case series, observational studies, etc.). The second body of evidence consisted of the characteristics present or less likely to be present in published cases of HPP.

Each diagnostic criterion was classified as being either:

- Essential or strongly suggestive of HPP
- May or may not be present or
- Not mentioned

Virtual meetings were held with the IWG to review the diagnostic characteristics and their suitability to function as major and minor criteria for the clinical diagnosis of HPP. A criterion was considered as a major diagnostic criterion if the pooled prevalence was greater than 50% of the published cases, or if the criteria was recommended by more than 50% of the studies. A minor diagnostic criterion was considered to be minor if the pooled prevalence was less than 50% or if it was recommended in 50% of the studies. The systematic review and consensus process for establishing the major and minor criteria for adults is provided in the accompanying article by Brandi et al. and for children in the accompanying article by Rush et al.

Major challenges in establishing the diagnostic criteria are the largely retrospective nature of the published literature, and small numbers of patients, resulting in low-quality data. The accompanying articles (Brandi et al. and Rush et al.) provide further details regarding the clinical application and limitations of the criteria chosen to confirm a diagnosis of HPP.

Major and Minor diagnostic criteria for HPP in adults and children:

In adults and children with a persistently low ALP for age and gender without any other identifiable cause, certain characteristics are suggested to be used as major and minor criteria for the diagnosis of HPP. In both children and adults, a combination of two major criteria or one major and two minor criteria can be used to establish the diagnosis of HPP (Table 4). It should be noted that these criteria represent the best knowledge of clinical signs and symptoms of HPP at the time of the literature review and creation of this manuscript. The authors acknowledge that our understanding of HPP will continue to evolve over time and it is anticipated that these guidelines will also be updated in approximately 5–6 years.

**Table 4** Diagnostic criteria for HPP in adults and children with persistently low ALP

Diagnostic criteria for HPP in adults (2 major or 1 major and 2 minor)	
Major	
Pathogenic or likely pathogenic <i>ALPL</i> gene variant	
Elevation of natural substrates ( <i>measurement of plasma vitamin B6 requires stopping pyridoxine supplementation 1 week prior to measurement</i> )	
Atypical femoral fractures (pseudofractures)	
Recurrent metatarsal fractures	
Minor	
Poorly healing fractures	
Chronic musculoskeletal pain	
Early atraumatic loss of teeth	
Chondrocalcinosis	
Nephrocalcinosis	
Diagnostic criteria for HPP in children (2 major or 1 major and 2 minor)	
Major	
Pathogenic or likely pathogenic <i>ALPL</i> gene variant	
Elevation of natural substrates ( <i>measurement of plasma vitamin B6 requires stopping pyridoxine supplementation 1 week prior to measurement</i> )	
Early nontraumatic loss of primary teeth	
Presence of rickets on radiographs	
Minor	
Short stature or linear growth failure over time	
Delayed motor milestones	
Craniosynostosis	
Nephrocalcinosis	
B6 responsive seizures	

## Summary

HPP is a rare inherited disorder with many multisystem manifestations, including impaired mineralization of bones and teeth. It has a variable presentation in children and adults. Unfortunately, the diagnosis is often missed or delayed. These individuals may have significant disease burden and we anticipate that earlier diagnosis will improve management and clinical outcome in adults and children. Utilizing the suggested major and minor criteria as detailed in the accompanying manuscripts (Brandt et al., Rush et al.) may enable early diagnosis of HPP. These suggested criteria require further validation and evaluation.

**Author contribution** Conceptualization and visualization: AAK, MLB, ETR; data curation, formal analysis, investigation, methodology, validation, and software: AAK, MLB, ETR, RBP, GG; project administration, funding acquisition, and resources: AAK, MLB, ETR; supervision: AAK, MLB, ETR; writing—original draft: AAK, MLB, ETR; writing—review and editing: AAK, MLB, ETR, DSA, HA, KA, FA, SB, KD, CD, SLF, FG, GG, EH, SWI, MKJ, SK, RK, AL, IM, FM, MEN, CRG, CR, LS, JHS, SRS, LMW, LY, RBP, EML.

**Funding** We acknowledge unrestricted financial support from Alexion via the International Osteoporosis Foundation (IOF). They had no input into the planning or design of the project, the conduct of the reviews, evaluation of the data, writing or review of the manuscript, its content, conclusions, or recommendations contained herein.

**Data availability** The data that support the findings in this study are openly available in PubMed, MEDLINE, EMBASE, and the Cochrane databases.

## Declarations

**Ethics approval** These papers are retrospective reviews and did not require ethics committee approval.

**Conflict of interest** AAK has received research grants from Alexion, Amgen, Ascendis, Chugai, Radius, Takeda, and Ultragenyx and is on the advisory board for Amgen, Amolyt, and Takeda. MLB has received honoraria from Amgen, Bruno Farmaceutici, Calcilytix, Kyowa Kirin, and UCB; grants and/or speaker for Abiogen, Alexion, Amgen, Bruno Farmaceutici, Echolight, Eli Lilly, Kyowa Kirin, SPA, Theramex, and UCB; Consultant for Aboca, Alexion, Amolyt, Bruno Farmaceutici, Calcilytix, Kyowa Kirin, and UCB. ETR has consulted for, received honoraria from, and has research supported by Alexion Pharmaceuticals, AstraZeneca Rare Disease. SB has received advisory board participation from Alexion. KMD has received research grants and honoraria from Alexion. CD serves as an investigator, consultant, and speaker for Amgen; investigator for Radius; speaker for Alexion. SWI has received grant funding and ad hoc advisory board participation from Alexion Pharmaceuticals. MKJ has received honoraria and grants from UCB, Amgen, Kyowa Kirin, Sanofi, Besin Healthcare, and Abbvie. RK is a speaker and has received research funding from Alexion, AstraZeneca Rare Disease. AL is a consultant for and has received research funding and honoraria from Alexion. MEN serves as a non-paid consultant (fee equivalent donated to 501(c)3 patient advocacy groups) for Alexion. CRG is a member of the Scientific Advisory Board of the HPP Global Patient Registry sponsored by Alexion AstraZeneca Rare Disease. She has had received honoraria for participation on this Board and has also received honoraria for select Alexion-sponsored presentations. CR has received research grants and honoraria from Alexion, Kyowa Kirin, and Regeneron. LS has received honoraria and grants from Alexion, Amgen, Chiesi, KyowaKirin, Novartis, Theramex, and UCB. JHS serves as an Investigator and consultant for Alexion. SRS has received honoraria from and has research supported by Alexion Pharmaceuticals, AstraZeneca Rare Disease. LMW serves as a consultant to Alexion. EML serves as an investigator, consultant, and speaker for Amgen; investigator for Radius; speaker for Alexion. DSA, HA, KA, FA, KD, SLF, FG, GG, EH, SK, IM, FM, LY, RBP declare no conflict of interest.

**Open Access** This article is licensed under a Creative Commons Attribution-NonCommercial 4.0 International License, which permits any non-commercial use, sharing, adaptation, distribution and reproduction in any medium or format, as long as you give appropriate credit to the original author(s) and the source, provide a link to the Creative Commons licence, and indicate if changes were made. The images or other third party material in this article are included in the article's Creative Commons licence, unless indicated otherwise in a credit line to the material. If material is not included in the article's Creative Commons licence and your intended use is not permitted by statutory regulation or exceeds the permitted use, you will need to obtain permission directly from the copyright holder. To view a copy of this licence, visit <http://creativecommons.org/licenses/by-nc/4.0/>.



## References

- Khan AA et al (2019) Hypophosphatasia: Canadian update on diagnosis and management. *Osteoporos Int* 30(9):1713–1722
- Bianchi ML et al (2020) Hypophosphatasia in adolescents and adults: overview of diagnosis and treatment. *Osteoporos Int* 31(8):1445–1460
- Whyte MP (2016) Hypophosphatasia — aetiology, nosology, pathogenesis, diagnosis and treatment. *Nat Rev Endocrinol* 12(4):233–246
- Rockman-Greenberg C (2013) Hypophosphatasia. *Pediatr Endocrinol Rev* 10(Suppl 2):380–388
- Seefried L et al (2020) Burden of illness in adults with hypophosphatasia: data from the Global Hypophosphatasia Patient Registry. *J Bone Miner Res* 35(11):2171–2178
- Whyte MP (2009) Atypical femoral fractures, bisphosphonates, and adult hypophosphatasia. *J Bone Miner Res* 24(6):1132–1134
- Bishop N (2015) Clinical management of hypophosphatasia. *Clin Cases Mineral Bone Metab : the official journal of the Italian Society of Osteoporosis, Mineral Metabolism, and Skeletal Diseases* 12(2):170–173
- Jemmerson R, Low MG (1987) Phosphatidylinositol anchor of HeLa cell alkaline phosphatase. *Biochemistry* 26(18):5703–5709
- Seetharam B, Tirupathi C, Alpers DH (1987) Hydrophobic interactions of brush border alkaline phosphatases: the role of phosphatidyl inositol. *Arch Biochem Biophys* 253(1):189–198
- Le Du MH, Millan JL (2002) Structural evidence of functional divergence in human alkaline phosphatases. *J Biol Chem* 277(51):49808–49814
- Orimo H (2010) The mechanism of mineralization and the role of alkaline phosphatase in health and disease. *J Nippon Med Sch* 77(1):4–12
- Fedde KN, Whyte MP (1990) Alkaline phosphatase (tissue-nonspecific isoenzyme) is a phosphoethanolamine and pyridoxal-5'-phosphate ectophosphatase: normal and hypophosphatasia fibroblast study. *Am J Hum Genet* 47(5):767–775
- Fedde KN et al (1999) Alkaline phosphatase knock-out mice recapitulate the metabolic and skeletal defects of infantile hypophosphatasia. *J Bone Miner Res* 14(12):2015–2026
- Lei W et al (2013) Alkaline phosphatases contribute to uterine receptivity, implantation, decidualization, and defense against bacterial endotoxin in hamsters. *Reproduction* 146(5):419–432
- Narisawa S, Yadav MC, Millán JL (2013) In vivo overexpression of tissue-nonspecific alkaline phosphatase increases skeletal mineralization and affects the phosphorylation status of osteopontin. *J Bone Miner Res* 28(7):1587–1598
- Millán JL (2013) The role of phosphatases in the initiation of skeletal mineralization. *Calcif Tissue Int* 93(4):299–306
- Fleisch H, Russell RG, Straumann F (1966) Effect of pyrophosphate on hydroxyapatite and its implications in calcium homeostasis. *Nature* 212(5065):901–903
- Sutton RA et al (2012) “Atypical femoral fractures” during bisphosphonate exposure in adult hypophosphatasia. *J Bone Miner Res* 27(5):987–994
- Bhattacharyya T et al (2016) Hypophosphatasia and the risk of atypical femur fractures: a case-control study. *BMC Musculoskelet Disord* 17:332
- Wong YW, Low MG (1994) Biosynthesis of glycosylphosphatidylinositol-anchored human placental alkaline phosphatase: evidence for a phospholipase C-sensitive precursor and its post-attachment conversion into a phospholipase C-resistant form. *Biochemical journal* 301(1):205–209
- Nosjean O et al (1997) Human tissue non-specific alkaline phosphatases: sugar-moiety-induced enzymic and antigenic modulations and genetic aspects. *Biochemical journal* 321(2):297–303
- Colazo JM et al (2019) Neurological symptoms in hypophosphatasia. *Osteoporos Int* 30(2):469–480
- Hofmann C et al (2013) Compound heterozygosity of two functional null mutations in the ALPL gene associated with deleterious neurological outcome in an infant with hypophosphatasia. *Bone* 55(1):150–157
- Sato M et al (2021) Tissue-nonspecific alkaline phosphatase, a possible mediator of cell maturation: towards a new paradigm. *Cells* 10(12):3338
- Whyte MP et al (2015) Hypophosphatasia: validation and expansion of the clinical nosology for children from 25 years experience with 173 pediatric patients. *Bone* 75:229–239
- Bowen RA et al (2010) Impact of blood collection devices on clinical chemistry assays. *Clin Biochem* 43(1–2):4–25
- Mohri M, Rezapoor H (2009) Effects of heparin, citrate, and EDTA on plasma biochemistry of sheep: comparison with serum. *Res Vet Sci* 86(1):111–114
- Eastell R et al (2011) Effects of denosumab on bone turnover markers in postmenopausal osteoporosis. *J Bone Miner Res* 26(3):530–537
- Kruse K et al (1989) Biochemical markers of bone turnover, intact serum parathyroid hormone and renal calcium excretion in patients with pseudohypoparathyroidism and hypoparathyroidism before and during vitamin D treatment. *Eur J Pediatr* 148(6):535–539
- Clarke BL (2014) Bone disease in hypoparathyroidism. *Arq Bras Endocrinol Metabol* 58(5):545–552
- Lum G (1995) Significance of low serum alkaline phosphatase activity in a predominantly adult male population. *Clin Chem* 41(4):515–518
- Osella G et al (1997) *Serum markers of bone and collagen turnover in patients with Cushing's syndrome and in subjects with adrenal incidentalomas*. *J Clin Endocrinol Metab* 82(10):3303–3307
- Bardin T (1992) Renal osteodystrophy, disorders of vitamin D metabolism, and hypophosphatasia. *Curr Opin Rheumatol* 4(3):389–393
- Siddique A, Kowdley KV (2012) Approach to a patient with elevated serum alkaline phosphatase. *Clin Liver Dis* 16(2):199–229
- Lund T et al (2010) Multiple myeloma: changes in serum C-terminal telopeptide of collagen type I and bone-specific alkaline phosphatase can be used in daily practice to detect imminent osteolysis\*. *Eur J Haematol* 84(5):412–420
- Shaver WA, Bhatt H, Combes B (1986) *Low serum alkaline phosphatase activity in Wilson's disease*. *Hepatology* 6(5):859–863
- Korman JD et al (2008) Screening for Wilson disease in acute liver failure: a comparison of currently available diagnostic tests. *Hepatology* 48(4):1167–1174
- Yücel D, Dalva K (1992) Effect of in vitro hemolysis on 25 common biochemical tests. *Clin Chem* 38(4):575–577
- Shapiro JR, Lewiecki EM (2017) Hypophosphatasia in adults: clinical assessment and treatment considerations. *J Bone Miner Res* 32(10):1977–1980
- Linglart A, Salles JP (2017) Hypophosphatasia: the contribution of imaging. *Arch Pediatr* 24(5S2):5S74–5S79
- Mannes I et al (2022) Imaging patterns in pediatric hypophosphatasia. *Pediatr Radiol* 52(5):998–1006
- Mornet E (2017) Genetics of hypophosphatasia. *Arch Pediatr* 24(5):5S51–5S56
- Taillandier A et al (2015) Molecular diagnosis of hypophosphatasia and differential diagnosis by targeted Next Generation Sequencing. *Mol Genet Metab* 116(3):215–220
- Payne RB (1998) Renal tubular reabsorption of phosphate (TmP/GFR): indications and interpretation. *Ann Clin Biochem: international journal of laboratory medicine* 35(2):201–206

45. Shaker JL et al (2015) Recent developments in osteogenesis imperfecta. *F1000Res* 4(F1000 Faculty Rev):681
46. Shapiro JR, Brennen F-S (2014) Chapter 55 - Osteogenesis imperfecta: maintenance of adult bone health. In: Shapiro JR et al (eds) *Osteogenesis imperfecta*. Academic Press, San Diego, pp 509–518
47. Mornet E (2007) Hypophosphatasia. *Orphanet J Rare Dis* 2(1):40
48. Mohn A et al (2011) Hypophosphatasia in a child with widened anterior fontanelle: lessons learned from late diagnosis and incorrect treatment. *Acta Paediatr* 100(7):e43–e46
49. Nield LS et al (2006) Rickets: not a disease of the past. *Am Fam Physician* 74(4):619–626
50. Carpenter TO et al (2011) A clinician's guide to X-linked hypophosphatemia. *J Bone Miner Res* 26(7):1381–1388
51. Reynolds RD et al (1991) Extremely low serum pyridoxal 5'-phosphate in children with familial hypophosphatemic rickets. *Am J Clin Nutr* 53(3):698–701
52. Tournis ST et al (2005) Co-existence of X-linked hypophosphatemic rickets (XLH) and primary hyperparathyroidism: case report and review of the literature. *J Musculoskelet Neuronal Interact* 5(2):150–154
53. Kramer K et al (2021) Dental defects in the primary dentition associated with hypophosphatasia from biallelic ALPL mutations. *Bone* 143:115732

**Publisher's Note** Springer Nature remains neutral with regard to jurisdictional claims in published maps and institutional affiliations.

## Authors and Affiliations

Aliya A. Khan<sup>1</sup> · Maria Luisa Brandi<sup>2,3</sup> · Eric T. Rush<sup>4,5,6</sup> · Dalal S. Ali<sup>1</sup> · Hatim Al-Alwani<sup>1</sup> · Khulod Almonaei<sup>1</sup> · Farah Alsarraf<sup>1</sup> · Severine Bacrot<sup>7</sup> · Kathryn M. Dahir<sup>8</sup> · Karel Dandurand<sup>9</sup> · Chad Deal<sup>10</sup> · Serge Livio Ferrari<sup>11</sup> · Francesca Giusti<sup>3</sup> · Gordon Guyatt<sup>12</sup> · Erin Hatcher<sup>13</sup> · Steven W. Ing<sup>14</sup> · Muhammad Kassim Javaid<sup>15</sup> · Sarah Khan<sup>16</sup> · Roland Kocijan<sup>17</sup> · Agnes Linglart<sup>18</sup> · Iman M'Hiri<sup>16</sup> · Francesca Marini<sup>2</sup> · Mark E. Nunes<sup>19</sup> · Cheryl Rockman-Greenberg<sup>20</sup> · Christian Roux<sup>21,22</sup> · Lothar Seefried<sup>23</sup> · Jill H. Simmons<sup>8</sup> · Susan R. Starling<sup>4</sup> · Leanne M. Ward<sup>24</sup> · Liang Yao<sup>12</sup> · Romina Brignardello-Petersen<sup>12</sup> · E. Michael Lewiecki<sup>25</sup>

✉ Aliya A. Khan  
aliya@mcmaster.ca

<sup>1</sup> Division of Endocrinology and Metabolism, McMaster University, Hamilton, Canada

<sup>2</sup> F.I.R.M.O. Italian Foundation for the Research On Bone Diseases, Florence, Italy

<sup>3</sup> Donatello Bone Clinic, Villa Donatello Hospital, Florence, Italy

<sup>4</sup> Division of Clinical Genetics, Children's Mercy Kansas City, Kansas City, MO, USA

<sup>5</sup> Division of Endocrinology, Metabolism, Osteoporosis and Genetics, Department of Internal Medicine, University of Kansas School of Medicine, Kansas City, KS, USA

<sup>6</sup> Department of Pediatrics, University of Missouri-Kansas City School of Medicine, Kansas City, MO, USA

<sup>7</sup> Department of Genetics, Centre Hospitalier de Versailles, Hôpital André Mignot, Versailles, France

<sup>8</sup> Division of Endocrinology and Metabolism, Vanderbilt University Medical Center, Nashville, TN, USA

<sup>9</sup> Department of Medicine, Endocrinology and Metabolism, Université de Sherbrooke, Sherbrooke, QC, Canada

<sup>10</sup> Center for Osteoporosis and Metabolic Bone Disease, Department of Rheumatology, The Cleveland Clinic Foundation, Cleveland, OH, USA

<sup>11</sup> Division of Bone Diseases, Department of Internal Medicine Specialties, Geneva University Hospitals and Faculty of Medicine, Geneva, Switzerland

<sup>12</sup> Department of Health Research Methods, Evidence and Impact at McMaster University, Hamilton, Canada

<sup>13</sup> Neuromuscular Clinic, McMaster University Medical Centre, Hamilton Health Sciences, Hamilton, Canada

<sup>14</sup> Division of Endocrinology, Diabetes & Metabolism, Ohio State University Wexner Medical Center, Columbus, OH, USA

<sup>15</sup> Nuffield Department of Orthopaedics, Rheumatology and Musculoskeletal Sciences, University of Oxford, Oxford, UK

<sup>16</sup> Bone Research and Education Centre, Oakville, ON, Canada

<sup>17</sup> Ludwig Boltzmann Institute of Osteology at Hanusch Hospital of OEGK and AUVA, Trauma Centre Meidling, 1st Medical Department Hanusch Hospital, 1140 Vienna, Austria

<sup>18</sup> APHP, Bicêtre Paris-Sud, University Paris Sud, Paris-Saclay, Le Kremlin Bicêtre, Paris, France

<sup>19</sup> Division of Medical Genetics and Metabolism, Valley Children's HealthCare, Madera, CA, USA

<sup>20</sup> Department of Pediatrics and Child Health, University of Manitoba, Winnipeg, MB, Canada

<sup>21</sup> Rheumatology Department, Hospital Pasteur 2 CHU, 06000 Nice, France

<sup>22</sup> Inserm, CNRS, iBV, Université Côte d'Azur, 06000 Nice, France

<sup>23</sup> Musculoskeletal Center Wuerzburg, University of Würzburg, Würzburg, Germany

<sup>24</sup> Children's Hospital of Eastern Ontario, Department of Pediatrics, University of Ottawa, Ottawa, ON, Canada

<sup>25</sup> New Mexico Clinical Research & Osteoporosis Center, Albuquerque, NM, USA