

Children's Mercy Kansas City

SHARE @ Children's Mercy

Manuscripts, Articles, Book Chapters and Other Papers

4-30-2024

Recurrent diffuse alveolar hemorrhage and extracorporeal membrane oxygenation utilization in a hematopoietic stem cell transplant patient with Hunter's syndrome.

Nasreen Noor

Children's Mercy Kansas City

Gene Peir

Children's Mercy Kansas City

Asdis Finnsdottir Wagner

Children's Mercy Hospital

Jay Rilinger

Children's Mercy Hospital

Jenna Miller

Children's Mercy Hospital

Let us know how access to this publication benefits you

Follow this and additional works at: <https://scholarlyexchange.childrensmercy.org/papers>



Part of the [Critical Care Commons](#), and the [Pediatrics Commons](#)

Recommended Citation

Noor N, Peir G, Wagner ÁF, Rilinger J, Miller J. Recurrent diffuse alveolar hemorrhage and extracorporeal membrane oxygenation utilization in a hematopoietic stem cell transplant patient with Hunter's syndrome. *Arch Clin Cases*. 2024;11(1):19-21. Published 2024 Apr 30. doi:10.22551/2024.42.1101.10281

This Article is brought to you for free and open access by SHARE @ Children's Mercy. It has been accepted for inclusion in Manuscripts, Articles, Book Chapters and Other Papers by an authorized administrator of SHARE @ Children's Mercy. For more information, please contact hlsteel@cmh.edu.

Recurrent diffuse alveolar hemorrhage and extracorporeal membrane oxygenation utilization in a hematopoietic stem cell transplant patient with Hunter's syndrome

Nasreen Noor, Gene Peir*, Ásdís Finnsdóttir Wagner, Jay Rilinger, Jenna Miller

Division of Critical Care, Children's Mercy Hospital, Kansas City, MO, USA; University of Missouri Kansas City, Kansas City, MO, USA.

*Correspondence: Gene Peir; Children's Mercy Hospital Division of Critical Care, 2401 Gillham Road, Kansas City, MO 64108, USA. Email: ghpeir@cmh.edu

How to cite this article: Noor N, Peir G, Finnsdóttir Wagner Á, et al. Recurrent diffuse alveolar hemorrhage and extracorporeal membrane oxygenation utilization in a hematopoietic stem cell transplant patient with Hunter's syndrome. Arch Clin Cases. 2024;11(1):19-21. doi: 10.22551/2024.42.1101.10281

ABSTRACT

We describe the natural history of a three-month-old patient with Hunter Syndrome with hematopoietic stem cell transplant (HSCT) who developed recurrent diffuse alveolar hemorrhage (DAH) requiring extracorporeal membrane oxygenation (ECMO). The patient underwent HSCT with several complications, including veno-occlusive disease and DAH. He was managed with ECMO. Unfortunately, despite initial success he developed recurrent DAH and ultimately died. This is a novel report of this severe adverse event requiring ECMO following the use of HSCT in this rare patient population. We share the clinical strategies employed to address the complications associated with HSCT and the progression of his disease over his hospitalization.

KEYWORDS: diffuse alveolar hemorrhage (DAH); extra corporal membrane oxygenation (ECMO); Hunter's syndrome; bone marrow transplant; pulmonary hemorrhage

INTRODUCTION

Hunter Syndrome is mucopolysaccharidosis (MPS) type II which can be associated with multi-organ dysfunction such as restrictive lung disease, cardiac valve disease, musculoskeletal abnormalities, and neurologic features such as cognitive decline [1]. There is literature that hematopoietic stem cell transplant (HSCT) can be effective in slowing neurocognitive decline [1] and extending life expectancies in Hurler Syndrome (MPS type I). However, unlike Hurler Syndrome, MPS guidelines did not previously recommend HSCT for Hunter Syndrome [2]. Instead, enzyme replacement therapy (ERT) has been the standard of care for this patient population. There is a paucity of recent literature regarding patients with Hunter Syndrome who received HSCT [1,3,4].

HSCT has many known complications, including diffuse alveolar hemorrhage (DAH) which is a severe pulmonary complication without a clear etiology post-HSCT. DAH appears more frequently in allogeneic HSCT for non-malignant diseases, especially in patients less than 1-year of age [5]. Possible etiologies are thought to be secondary to inflammation and/or cytokine release as seen in Graft Versus Host Disease (GVHD), Transplant-Associated Thrombotic

Microangiopathy (TA-TMA), pulmonary toxic agents, and/or infection [5].

In a 2017 retrospective review of 146 MPS type II patients (both previously published and novel), there was no report of diffuse alveolar hemorrhage (DAH) or use of extracorporeal membrane oxygenation (ECMO) [1]. We describe the natural history of a patient with MPS Type II who received a HSCT, developed DAH and was cannulated to ECMO. Despite initial success in treating the DAH permitting separation from ECMO, he developed recurrent episodes and ultimately died despite intensive therapies. To our knowledge this is a novel report of this severe adverse event requiring ECMO support following the use of HSCT in this rare patient population. We add to the literature surrounding this therapy in Hunter Syndrome and its possible side effects and share our clinical management strategies.

CASE PRESENTATION

A three-month-old infant with newborn screen diagnosed Hunter Syndrome was admitted for an allogeneic matched unrelated cord blood transplant. He was conditioned with busulfan, cyclophosphamide and anti-thymocyte globulin and maintained on idursulfase enzyme replacement therapy. He underwent HSCT on hospital day (HD) 15 and was initiated on GVHD prophylaxis including tacrolimus and mycophenolate mofetil. On HD 17, he was transferred to the PICU for worsening respiratory failure secondary to a combination of

Received: November 2023; **Accepted after review:** March 2024;
Published: March 2024.



suspected mucositis, new rhinovirus/enterovirus bronchiolitis, inadequate pain control, and fluid overload. His weight was approximately 8kg.

On HD 20, he developed veno-occlusive disease (VOD) requiring a peritoneal drain and was initiated on defibrotide (5 mg/kg q6h) therapy. On HD 28, he had an acute respiratory decompensation due to DAH (Figure 1).

After securing the airway he remained desaturated despite 100% FiO₂ on high conventional ventilator settings with an oxygenation index greater than 30. In addition, he became hypotensive requiring multiple code doses of epinephrine along with initiation of epinephrine and norepinephrine infusions. Per our institutional standard, we held a multi-disciplinary huddle and decided to cannulate him onto veno-arterial ECMO for persistent hypoxia and hypotension. He was cannulated through his right internal jugular vein and carotid artery and started on bivalirudin for circuit anticoagulation while defibrotide was held. His DAH was initially managed with high PEEP of 14 and minimal PC with inhaled tranexamic acid (TXA; 250 mg q6h) and maintaining platelets >100,000/mcL, fibrinogen >150-200 mg/dL, and hematocrit >32%; however, he continued to have bloody tracheal secretions. On HD 32 (ECMO day 3), the decision was made to clamp his cuffed endotracheal tube (ETT) for 12 hours, a technique previously trialed in the literature [6]. Following the clamping his bleeding abated, and he had reinflation of his lungs on CXR and return of tidal volumes. On bronchoscopy on HD 34 (ECMO day 5), he had no signs of active bleeding. He was able to wean his ECMO support and on HD 35 was decannulated after a one-week ECMO course. Of note, after decannulation, his vessels were not repaired per institutional standard procedure (Figure 2).

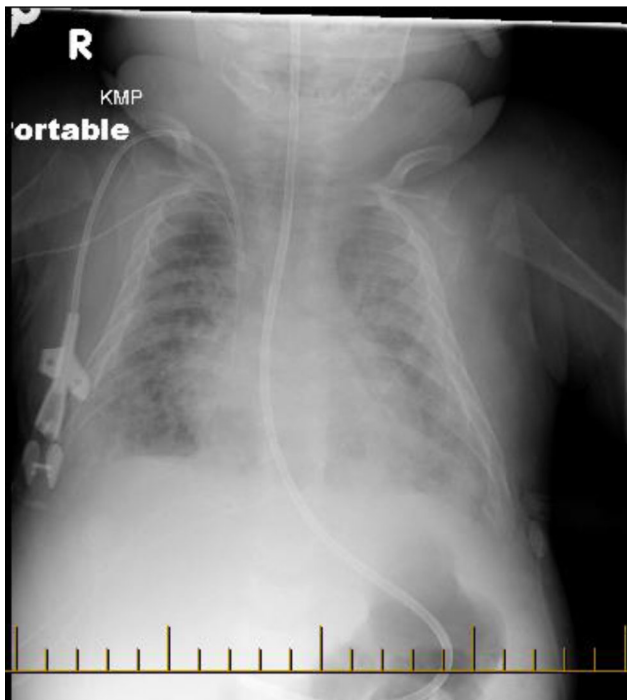


Fig. 1. HD 28, Chest X-ray showing diffuse bilateral pulmonary infiltrates.

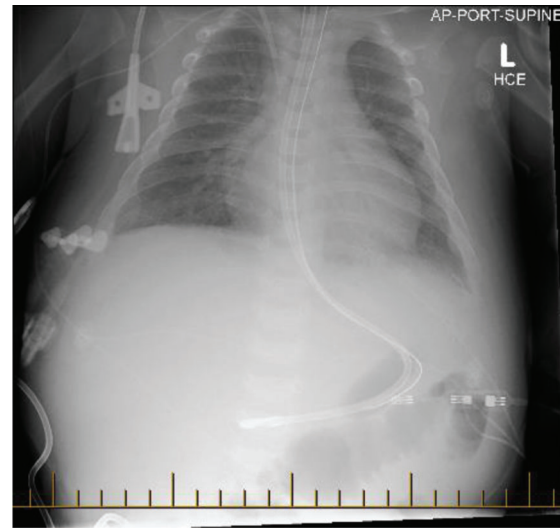


Fig. 2. On HD 35 Chest XR showing improved lung aeration after ECMO decannulation.

Following his decannulation he developed hyperammonemia and acute kidney injury of unclear etiology requiring continuous renal replacement therapy with continuous venovenous hemodiafiltration and single pass albumin dialysis for 11 days.

On HD 49, he was extubated and did well for several hours, but had a recurrence of DAH requiring re-intubation that evening. Of note, he was not on systemic anticoagulation or defibrotide at that time, and infectious etiologies were ruled out. With high conventional ventilation settings, inhaled TXA (250 mg q6h), a TXA IV push (75 mg) and continuous infusion (1 mg/kg/hr) and inhaled recombinant activated Factor VIIa (Novo7; 260 mcg), his DAH abated. He did, however, continue to struggle with oxygenation and ventilation. After a treatment course for suspected thrombotic microangiopathy which included eculizumab (300 mg/dose), infliximab (75 mg/dose), and four consecutive 1.0 volume therapeutic plasma exchanges daily, his pulmonary hemorrhage recurred. His oxygenation and ventilation continued to worsen despite all therapies and transition to both airway pressure-release ventilation and high-frequency oscillatory ventilation. The family ultimately redirected toward comfort care on HD 79. An autopsy was offered to the family, which they declined.

■ DISCUSSION

We describe the natural history of a three-month-old with Hunter Syndrome who underwent HSCT and developed DAH, requiring ECMO support. There is evidence to suggest that HSCT may result in favorable outcomes in Hurler Syndrome [1]; however, much less evidence exists for Hunter Syndrome. Although Hurler Syndrome and Hunter Syndrome are both mucopolysaccharidoses, there are variations in their pathophysiology and have had different guidelines regarding treatment, notably regarding HSCT candidacy. More recently, HSCT has increasingly been considered for use in the Hunter syndrome population [4].

To our knowledge, there are no reports of Hunter patients developing DAH after HSCT, and only one described case of a patient on ECMO support for heart failure [7]. In a recent

review of 146 Hunter Syndrome patients undergoing HSCT, 9 patients died; there were no reports of DAH or ECMO use [4].

Historically, HSCT in pediatric patients was considered a contraindication for ECMO cannulation. However, there has been a shift in the Extracorporeal Life Support Organization (ELSO) guidelines regarding ECMO candidacy for pediatric patients receiving HSCT [8]; this patient population may be considered an ECMO candidate after a multi-disciplinary discussion regarding underlying disease pathology and prognosis. We believe this ECMO run was successful in providing ongoing oxygenation and ventilatory support to allow DAH treatment therapies time to take effect; additionally, being supported on ECMO allowed trials of less conventional techniques such as clamping the endotracheal tube. Unfortunately, this patient's DAH did recur multiple times following the initial successful management with ECMO. Previous MPS guidelines did not recommend HSCT for Hunter Syndrome, and if this recommendation is to be reconsidered, it remains important to report adverse events.

CONCLUSION

Despite this patient's poor outcome, we have provided more data about a natural history in a patient with Hunter Syndrome after HSCT who then developed DAH requiring ECMO support. This case can be used as a reference for providers who are considering ECMO in this patient population.

Informed Consent

Written informed consent was obtained from the patient's family for publication of this case report and accompanying images. A copy of the written consent is available for review by the Editor-in-Chief of this journal.

Acknowledgements and Disclosures

No author for this paper has accepted reimbursement/fees/funds/salaries from an organization that may in any

way gain or lose financially from the results reported in the reviewed manuscript. There are no other competing financial or non-financial interests. The Authors declare that there is no conflict of interest.

REFERENCES

1. Kubaski F, Yabe H, Suzuki Y, et al. Hematopoietic Stem Cell Transplantation for Patients with Mucopolysaccharidosis II. *Biol Blood Marrow Transplant.* 2017 Oct;23(10):1795-1803. PMID: 28673849; PMCID: PMC5659208. doi: 10.1016/j.bbmt.2017.06.020.
2. Peters C, Steward CG; National Marrow Donor Program; International Bone Marrow Transplant Registry; Working Party on Inborn Errors, European Bone Marrow Transplant Group. Hematopoietic cell transplantation for inherited metabolic diseases: an overview of outcomes and practice guidelines. *Bone Marrow Transplant.* 2003 Feb;31(4):229-239. PMID: 12621457. doi: 10.1038/sj.bmt.1703839.
3. Guffon N, Bertrand Y, Forest I, et al. Bone marrow transplantation in children with Hunter syndrome: outcome after 7 to 17 years. *J Pediatr.* 2009 May;154(5):733-737. PMID: 19167723. doi: 10.1016/j.jpeds.2008.11.041.
4. Barth AL, Horovitz DDG. Hematopoietic Stem Cell Transplantation in Mucopolysaccharidosis Type II: A Literature Review and Critical Analysis. *Journal of Inborn Errors of Metabolism and Screening.* 2018;6. doi: 10.1177/2326409818779097.
5. Fan K, McArthur J, Morrison RR, et al. Diffuse Alveolar Hemorrhage After Pediatric Hematopoietic Stem Cell Transplantation. *Front Oncol.* 2020 Sep 9;10:1757. PMID: 33014865; PMCID: PMC7509147. doi: 10.3389/fonc.2020.01757.
6. Vobruba V, Grus T, Mlejnsky F, et al. Management of severe pulmonary hemorrhage in a neonate on veno-arterial ECMO by the temporary clamping of the endotracheal tube - a case report. *Perfusion.* 2018 Jan;33(1):77-80. PMID: 28816096. doi: 10.1177/0267659117723453.
7. Biswas A, Shrestha P. Hunter's syndrome presenting as heart failure: A case report. *Intl J Case Rep Imag* 2013;4(6):321-325. doi: 10.5348/ijcri-2013-06-322-CR-7.
8. Di Nardo M, Ahmad AH, Merli P, et al. Extracorporeal membrane oxygenation in children receiving haematopoietic cell transplantation and immune effector cell therapy: an international and multi-disciplinary consensus statement. *Lancet Child Adolesc Health.* 2022 Feb;6(2):116-128. PMID: 34895512; PMCID: PMC9372796. doi: 10.1016/S2352-4642(21)00336-9.